

**SERVIZIO SANITARIO REGIONALE
EMILIA-ROMAGNA**
Azienda Ospedaliero - Universitaria di Ferrara



università di ferrara
DA SEICENTO ANNI GUARDIAMO AVANTI.

Neuroradiologia Interventistica

Dr. Andrea Saletti

**Dirigente Medico I livello
Funzione di alta specialità**

**U.O Neuroradiologia (Direttore Dr.Riccardo Tamarozzi)
Dipartimento di Neuroscienze e Riabilitazione
Azienda Ospedaliero Universitaria S.Anna Ferrara**

1936 primo intervento programmato su un
Aneurisma Intracranico con clip di argento



Walter Dandy

1964 Prime “navigazioni endovascolari” intracraniche
Luessenhop e Velasquez
Neurochirurghi Georgetown University Hospital
(Washington D.C)



1974 Primo intervento endovascolare
di aneurisma cerebrale trattato con
palloncino staccabile

Prof. Serbinenko

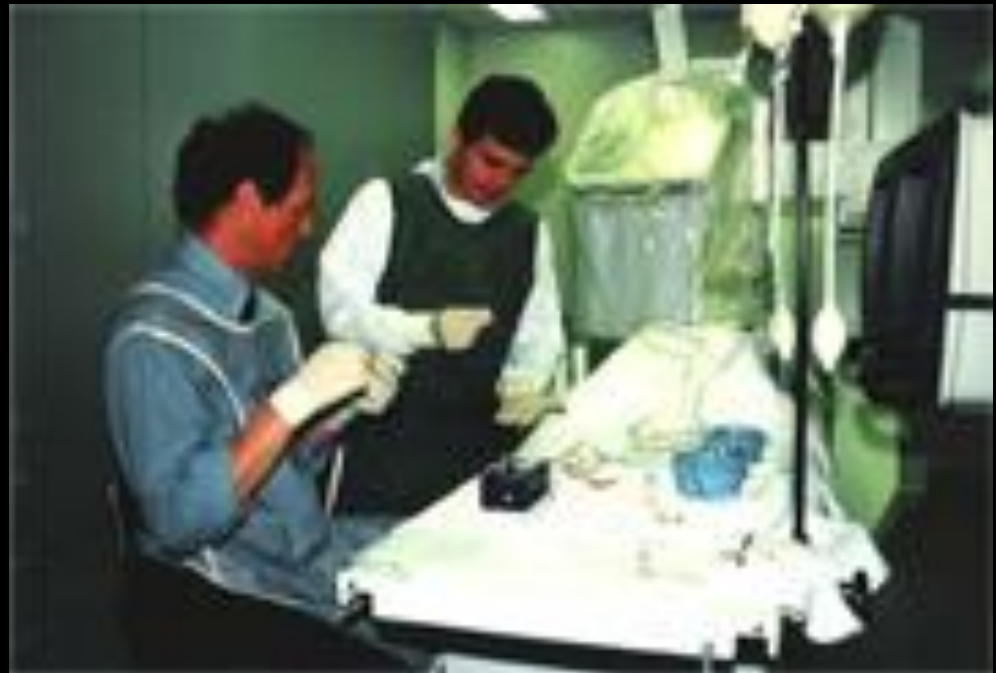

René Djindjian
1918–1977

1977, Giuseppe Scialfa, all'Ospedale Niguarda di Milano, inizia le embolizzazioni delle fistole carotido-cavernose con i palloncini staccabili di Debrun.

1983, Guido Guglielmi presenta i primi risultati sperimentali dell'elettrocoagulazione. Questa sua ricerca lo porterà a presentare al Symposium Neuroradiologicum di Londra la proposta di embolizzazione degli aneurismi endocranici con spirali staccabili.

La ricerca relativa, che ha avuto un grandissimo successo mondiale, viene sviluppata da Guglielmi all'Università di Los Angeles dove egli si trasferisce verso la fine degli anni '80.





AVBC-WIM seminar
Since 1980
Val d'Isère





Prof. Casasco
Parigi Hopital La pitie Salpetriere



Prof. Houdart
Parigi Hopital La Riboisiere



Italia

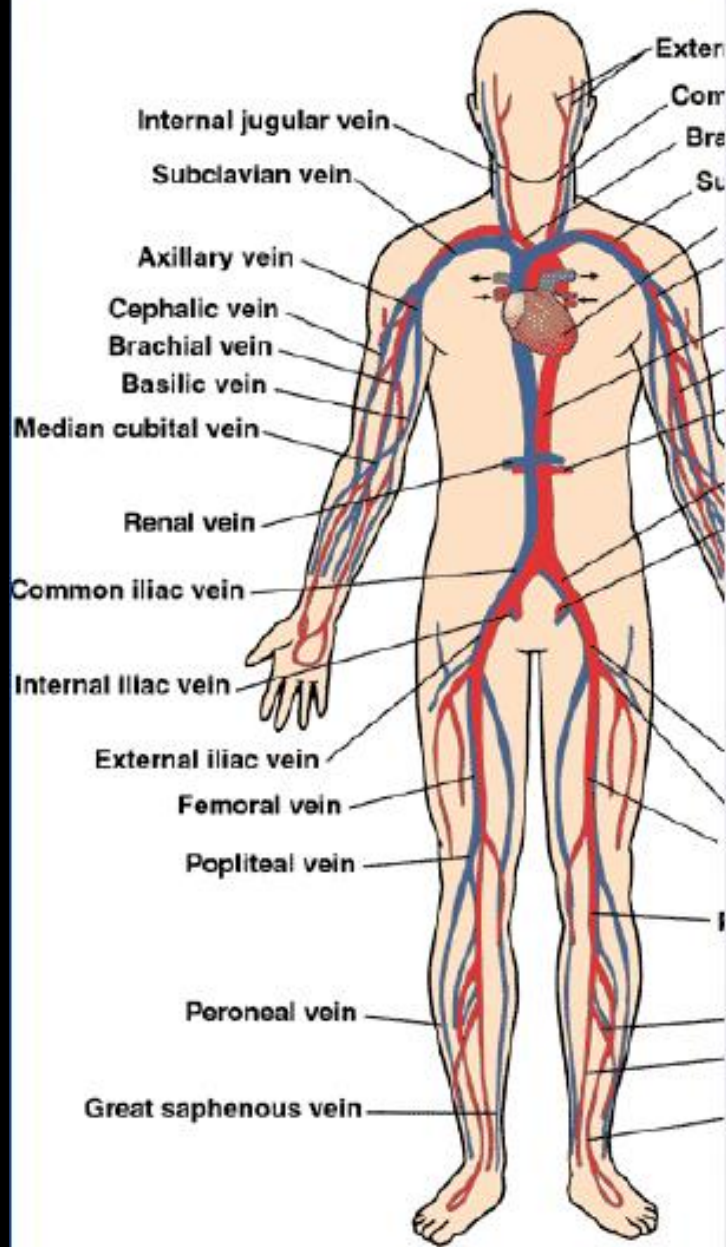
134 Centri di Neurochirurgia

60 Centri di Neuroradiologia attrezzati per terapie endovascolari

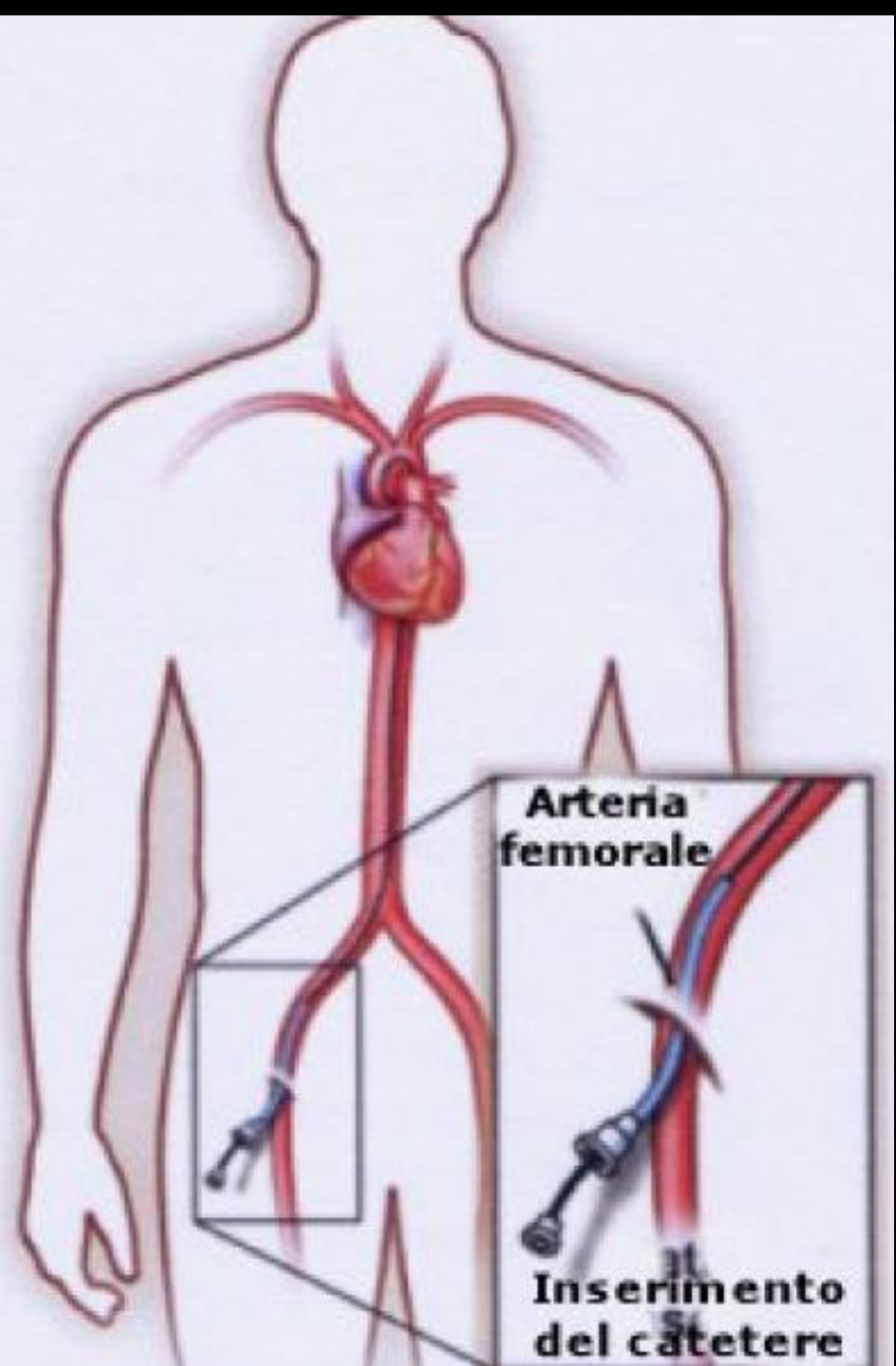
75 Neuroradiologi Interventisti

Dati 2008

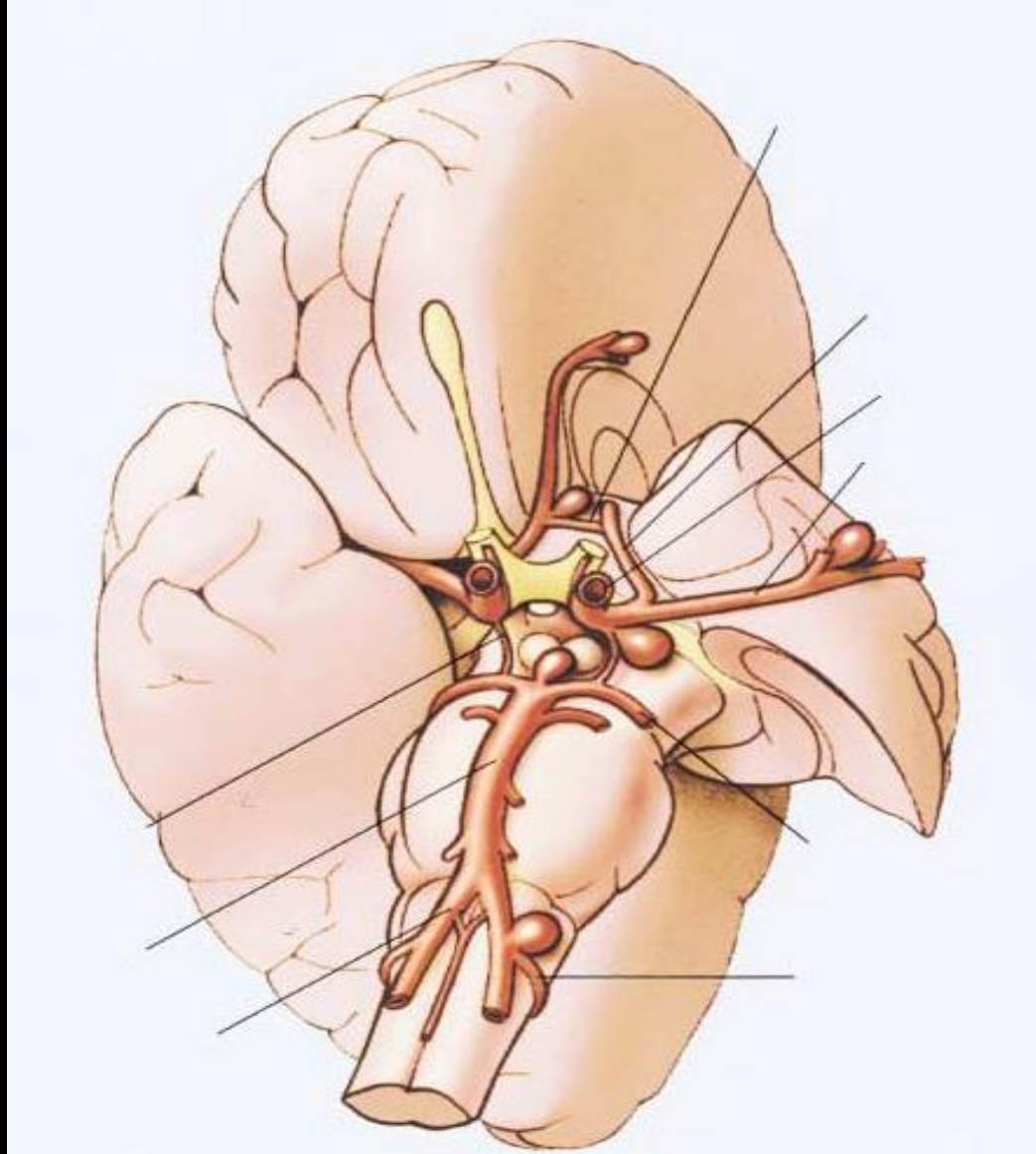
Circulatory System



Copyright © 2002 McKesson Health Solutions, LLC. All Rights Reserved.



ANEURISMI CEREBRALI



EMORRAGIA SUBARACNOIDEA

5% di tutti gli stroke

Picco di incidenza 40-60 anni

10/100.000 abitanti per anno

Femmine/Maschi 1.6/1

40% decede prima del ricovero

Indice di mortalità a 30 gg 50%

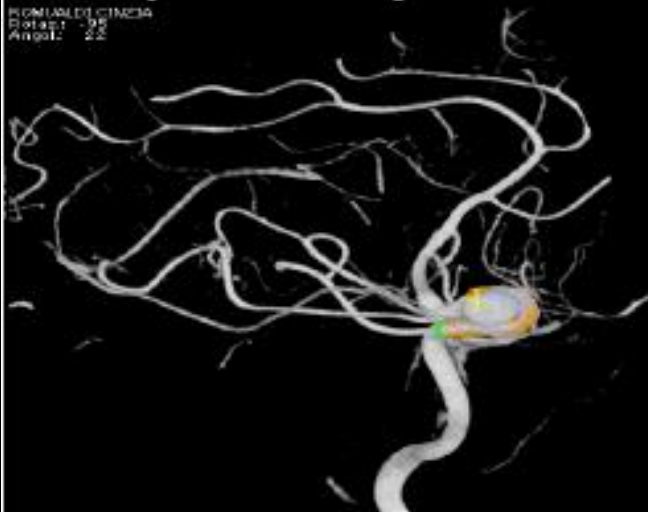
Fra i sopravvissuti 50% disabilità

Aneurismi cerebrali Clip or coil? Trattamento endovascolare

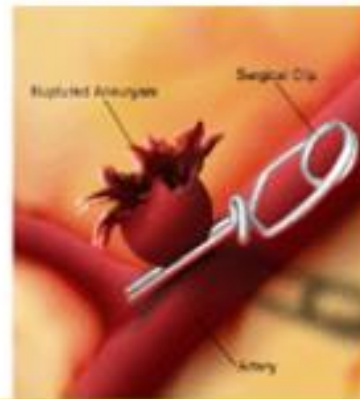
-Vantaggi terapeutici

- Minor invasività
- Velocità (45' - 120')
- Più aneurismi nella stessa seduta
- Integrazione diagnostico-terapeutica (ultra-early)

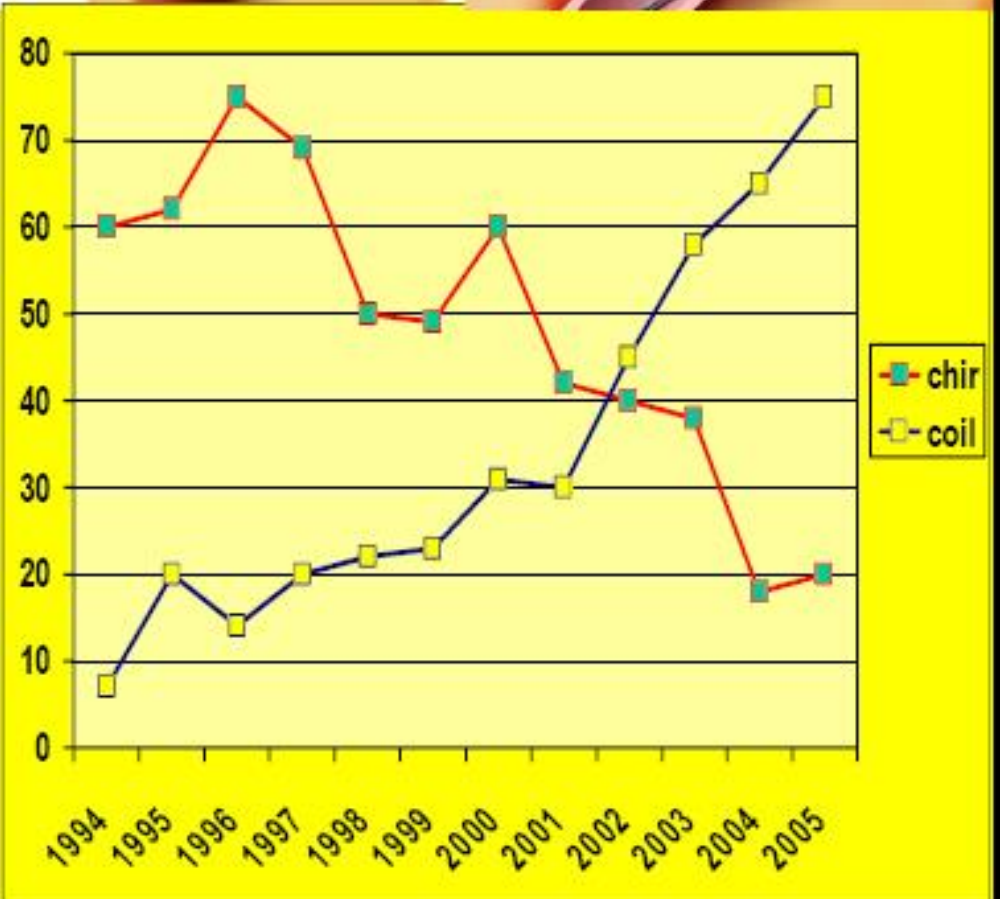
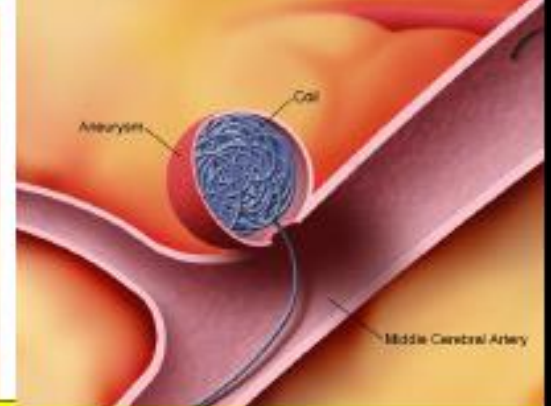INOMIABLE CTM239
2014/17 22
Angiol 22

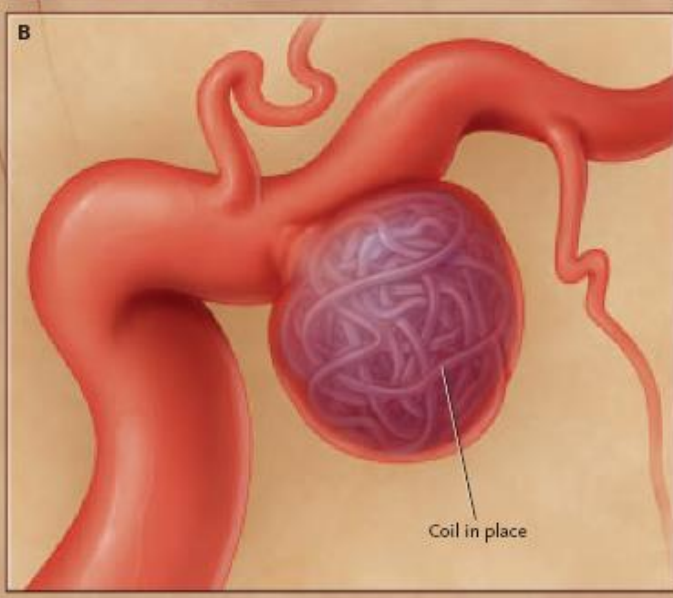
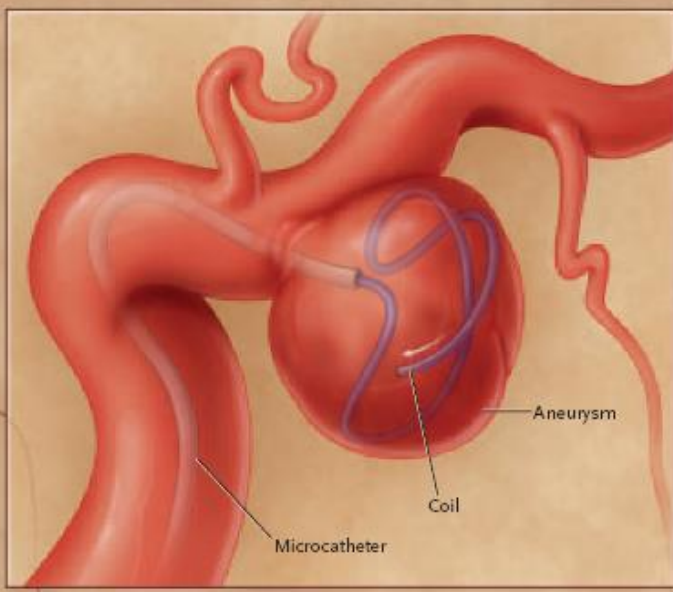
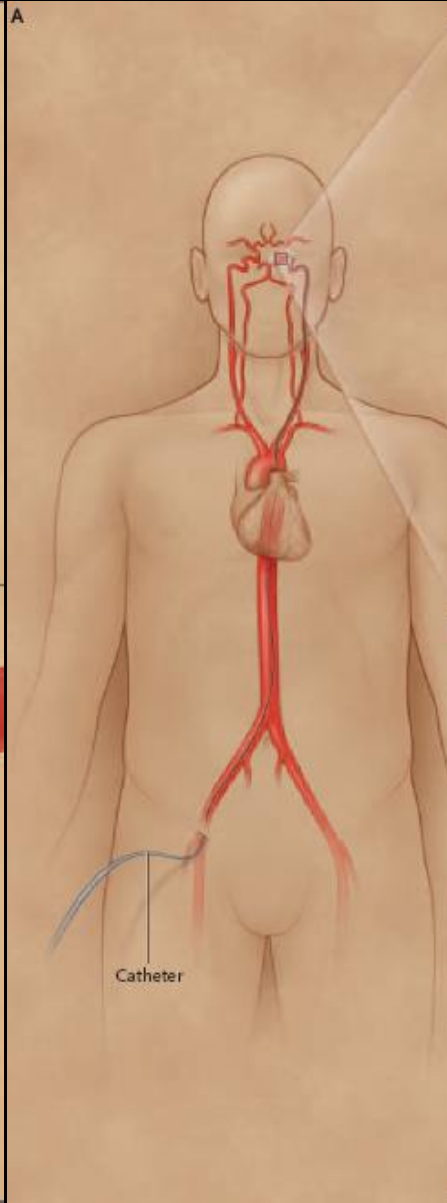
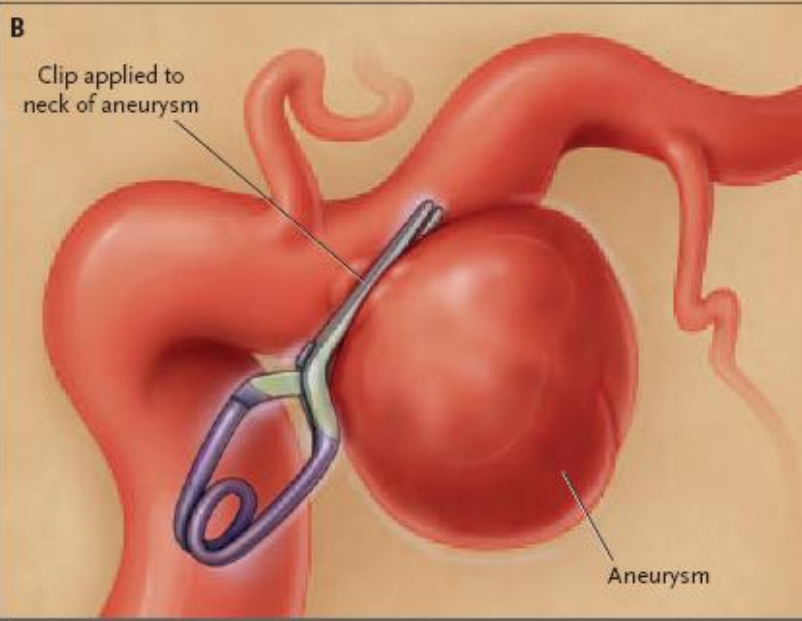
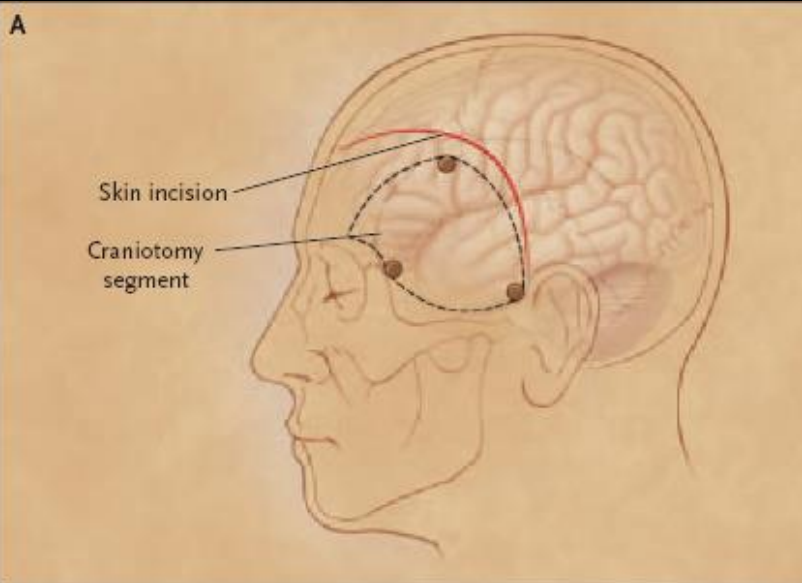


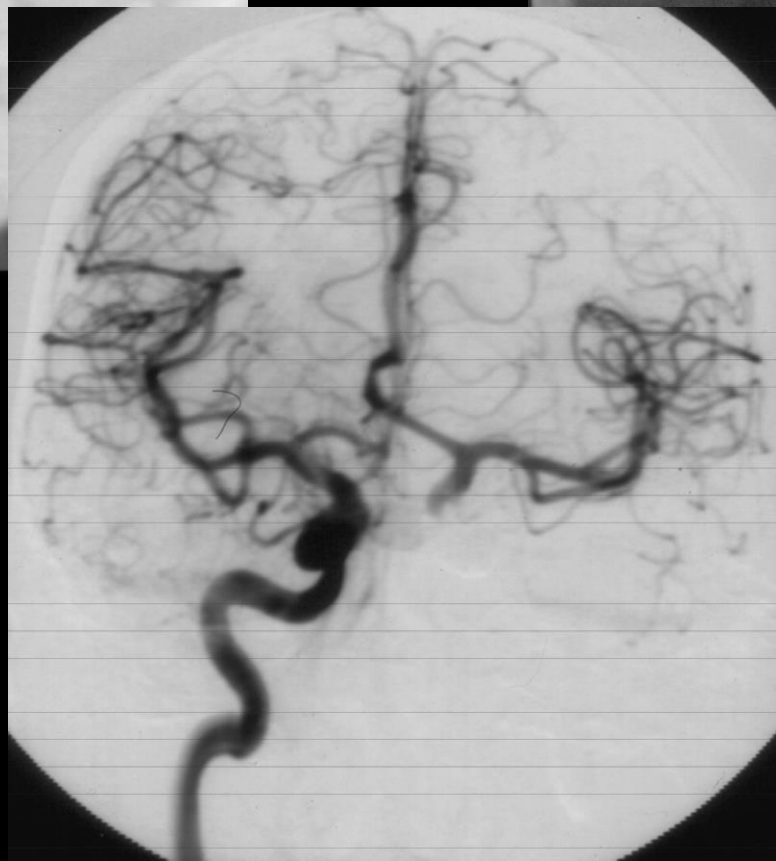
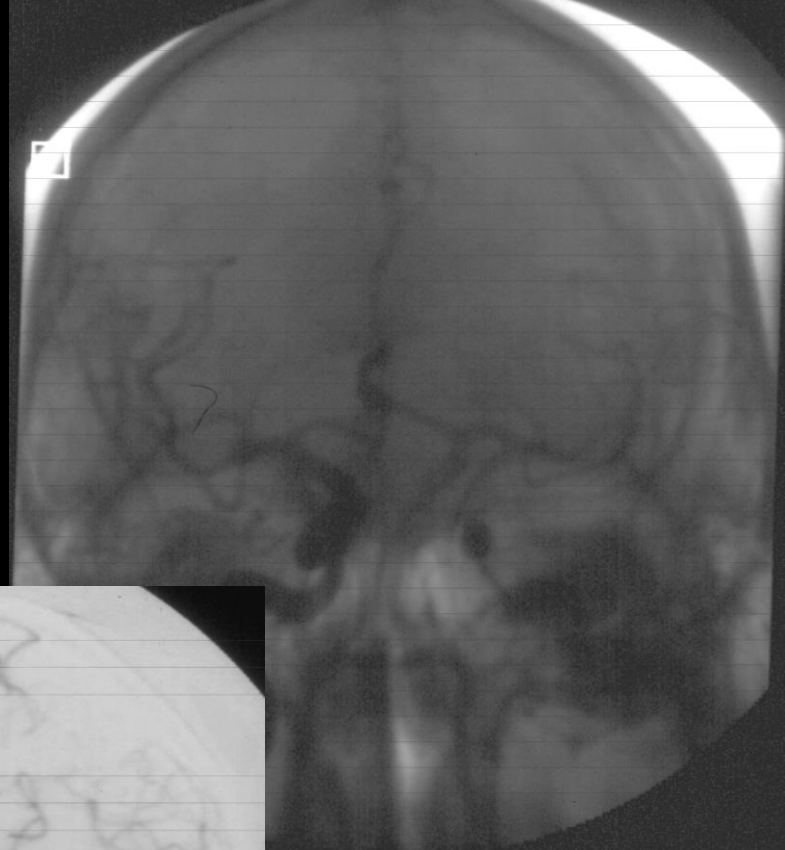
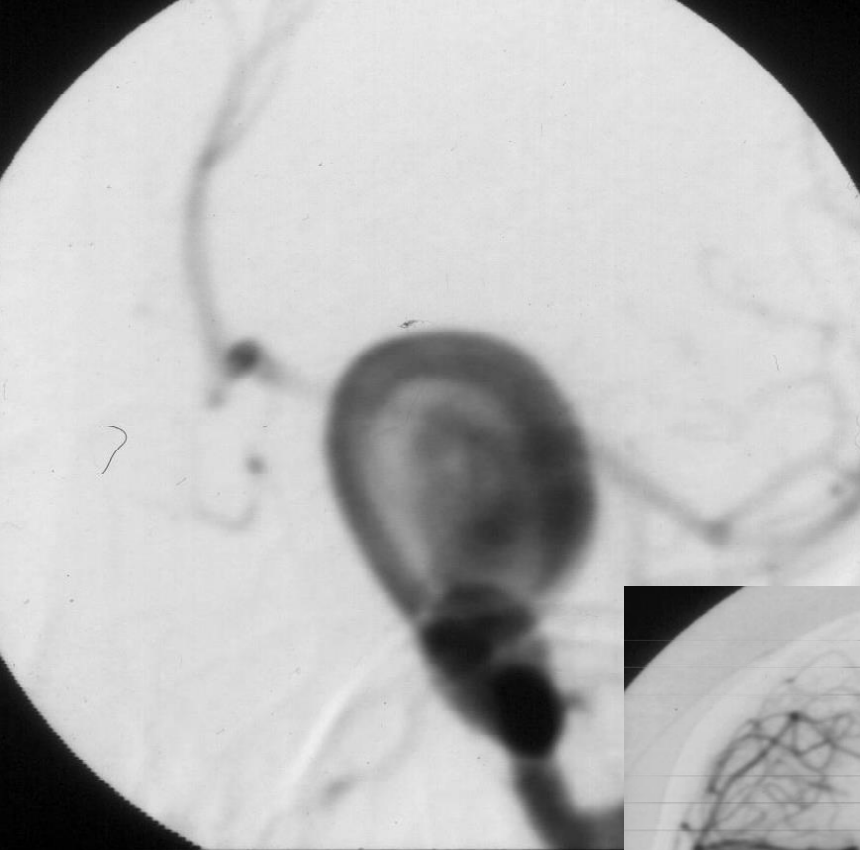Clipping Treatment for Cerebral Aneurysm



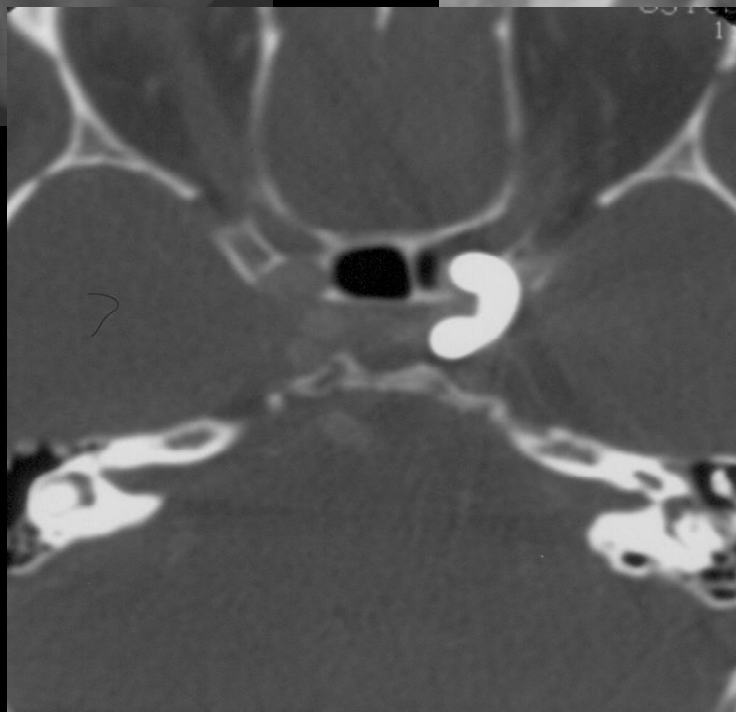
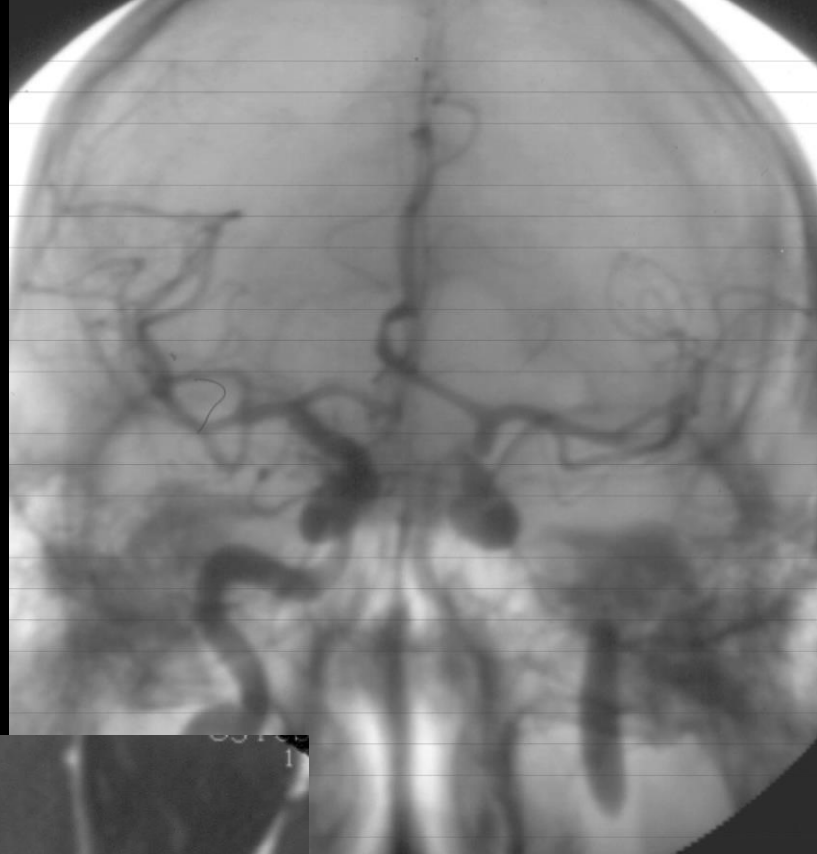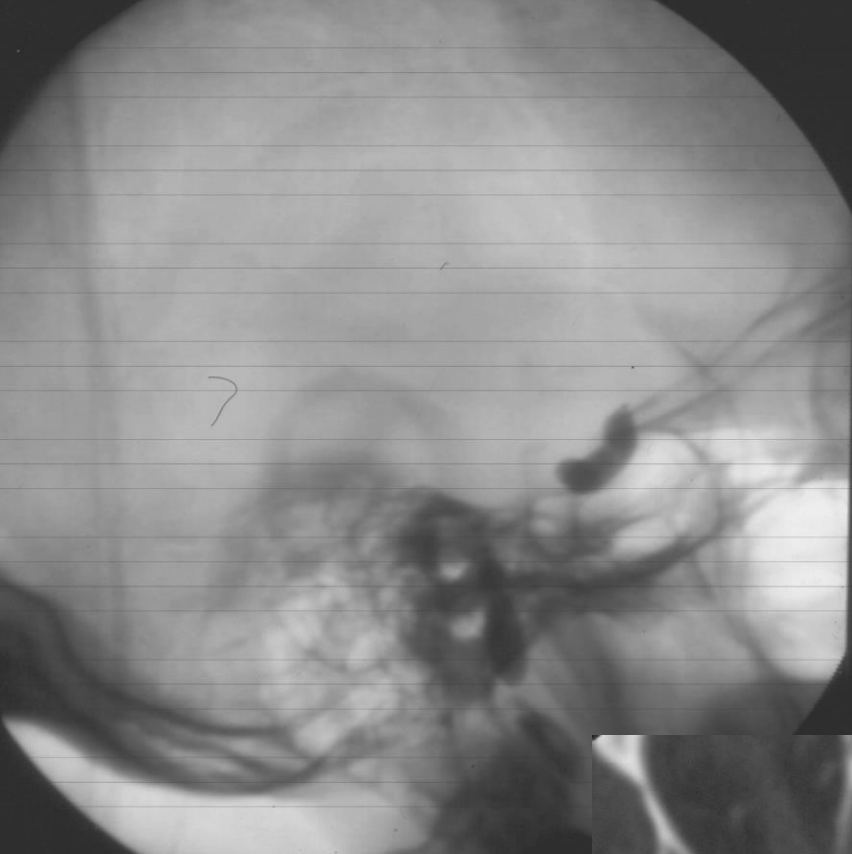Coil Procedure for Cerebral Aneurysm



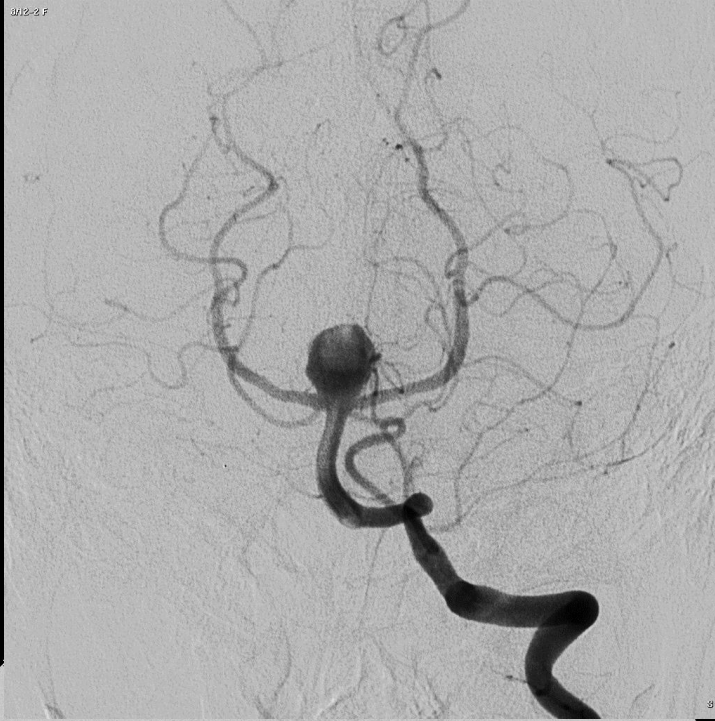



Gennaio 2000
Uomo 38 aa
ESA + ematoma
fronto basale

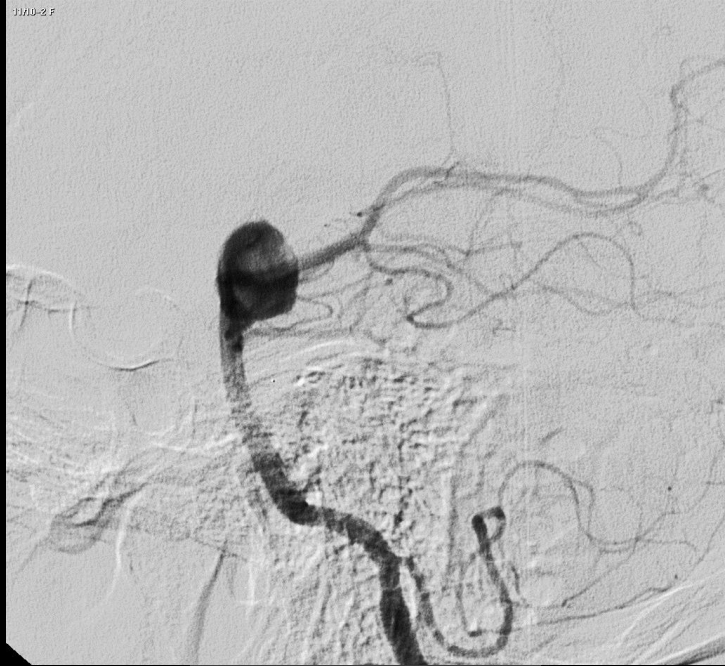

0112-2 F

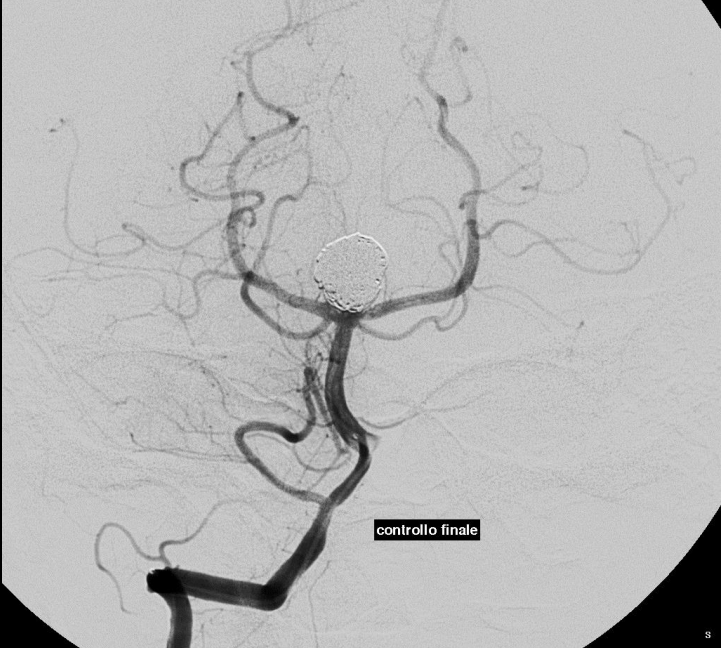

31

1110-2 F

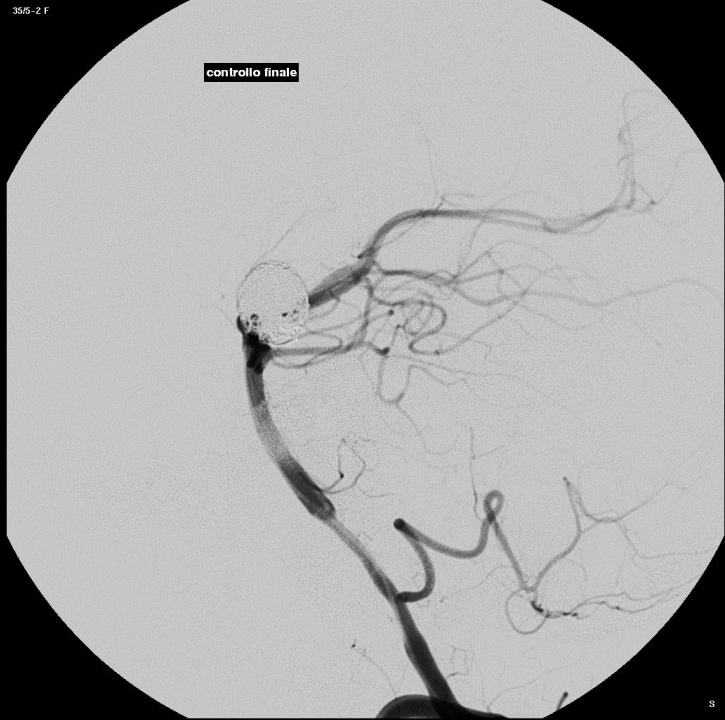

355-2 F



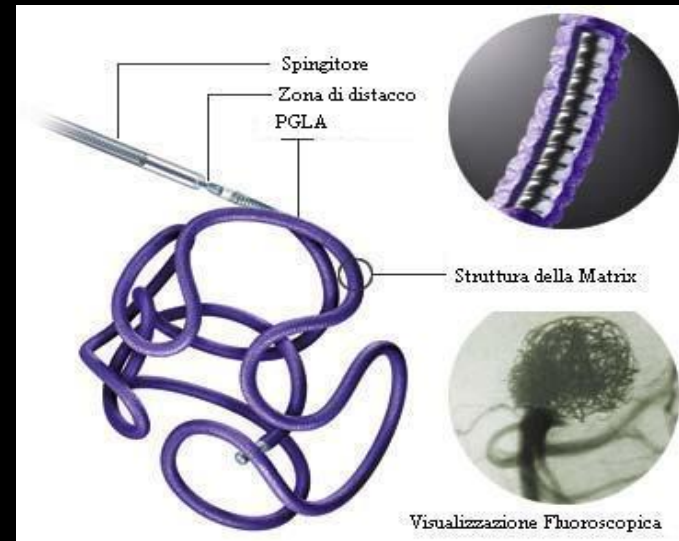
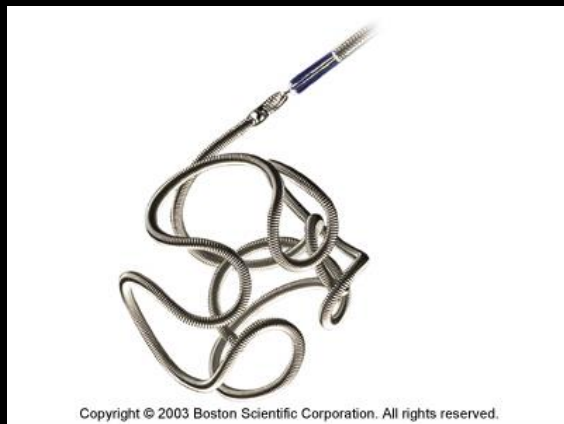
controllo finale

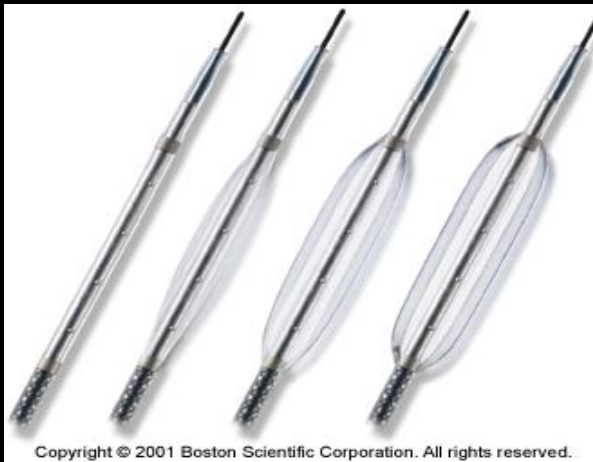32



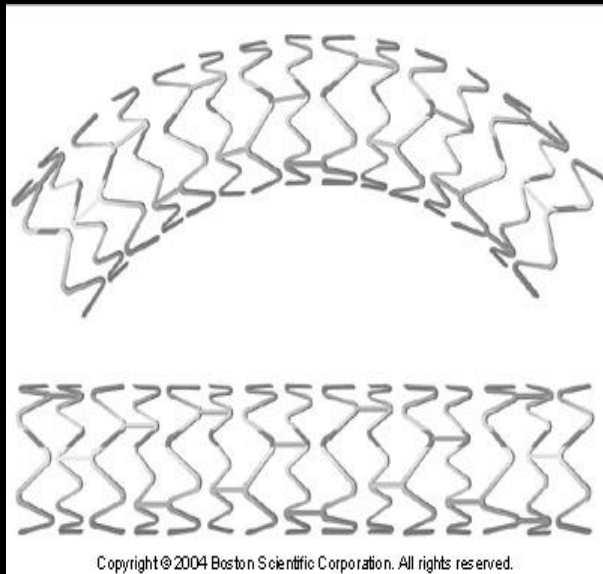
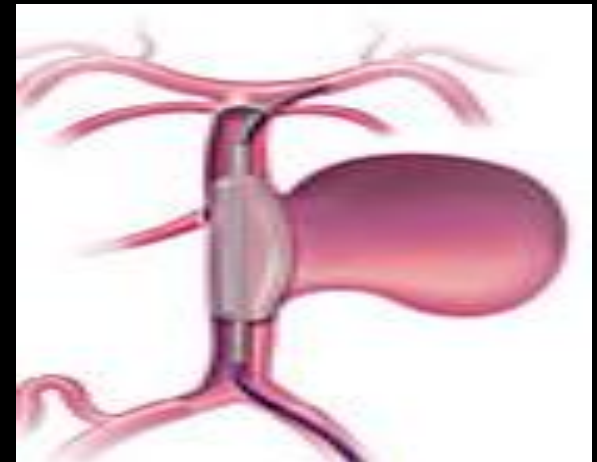
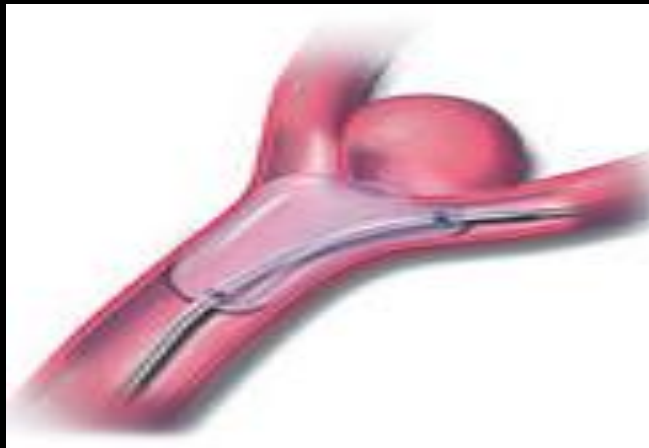controllo finale

33

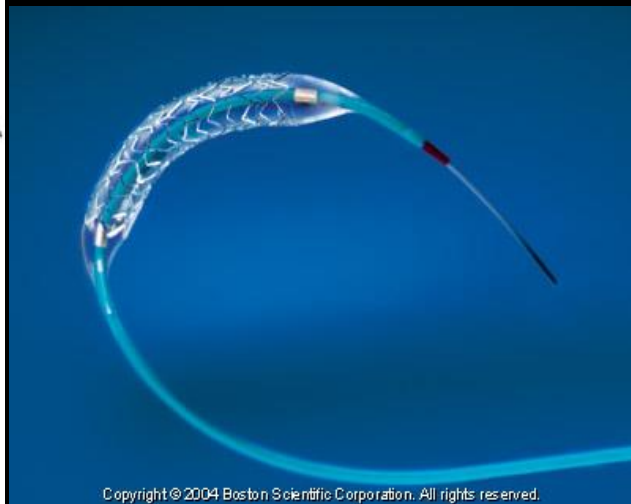



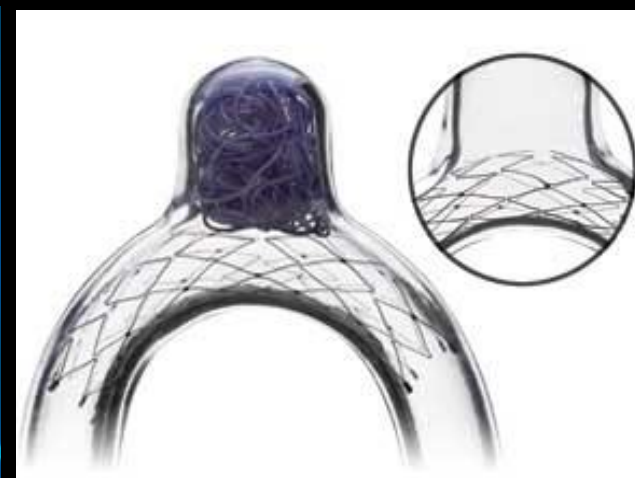Copyright © 2001 Boston Scientific Corporation. All rights reserved.



Copyright © 2004 Boston Scientific Corporation. All rights reserved.



Copyright © 2004 Boston Scientific Corporation. All rights reserved.



(A)



Embolizzazione con palloncino

(B)

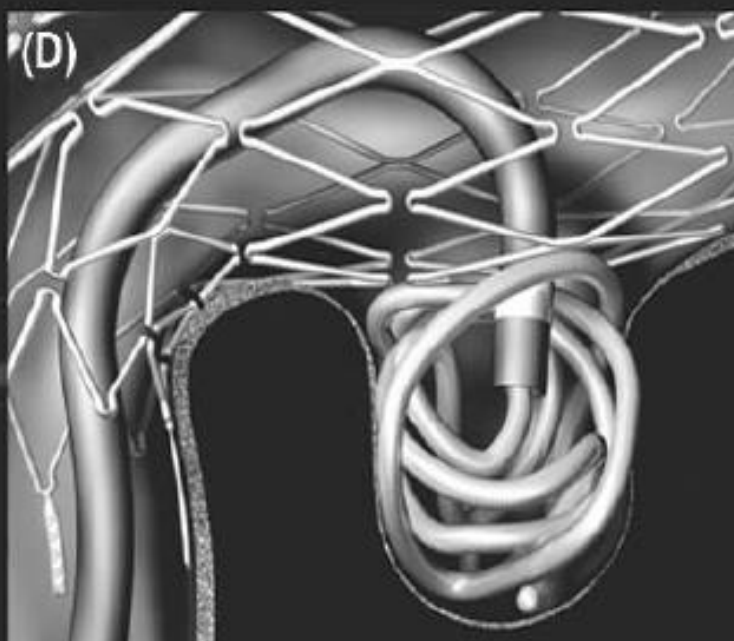


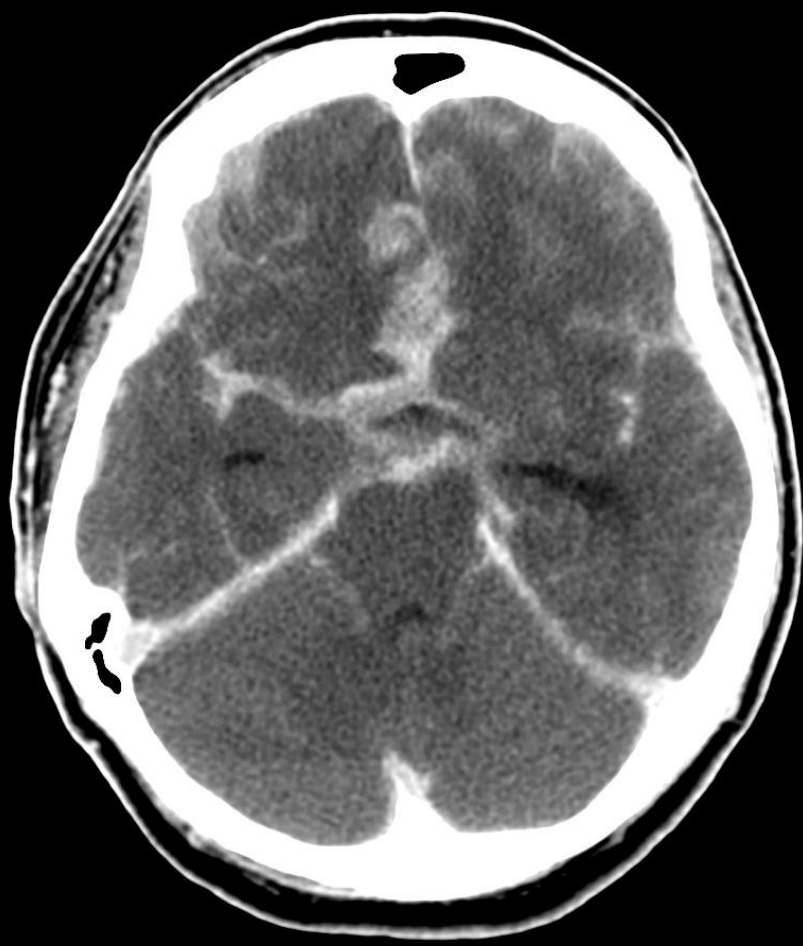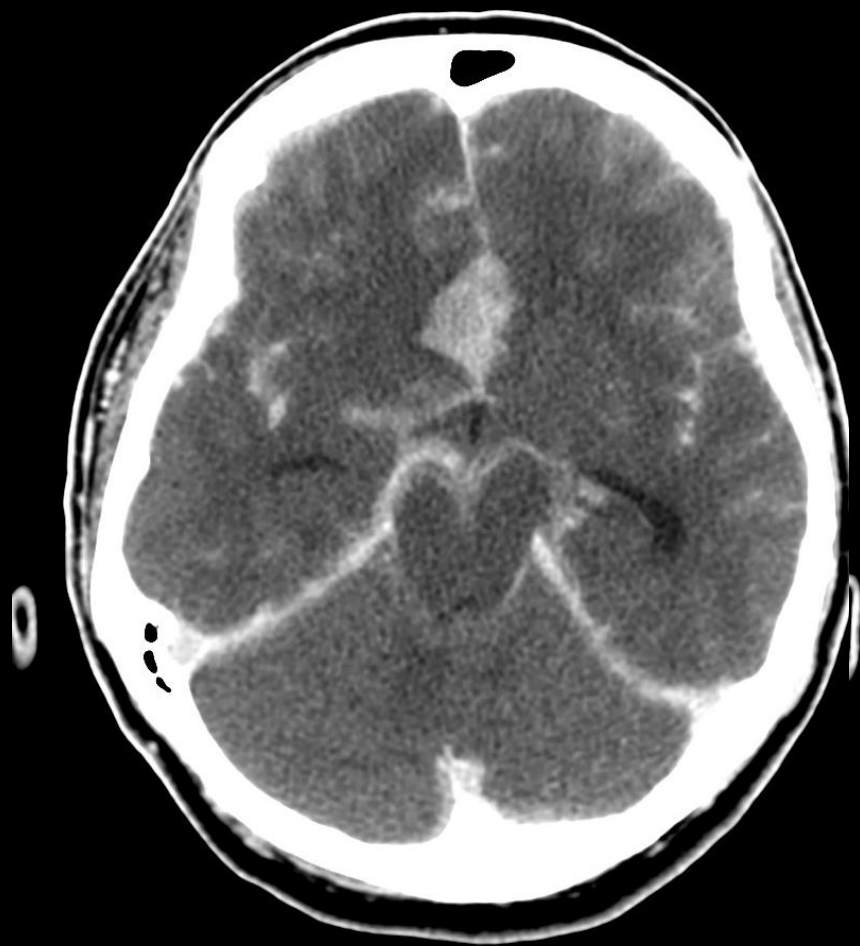(C)

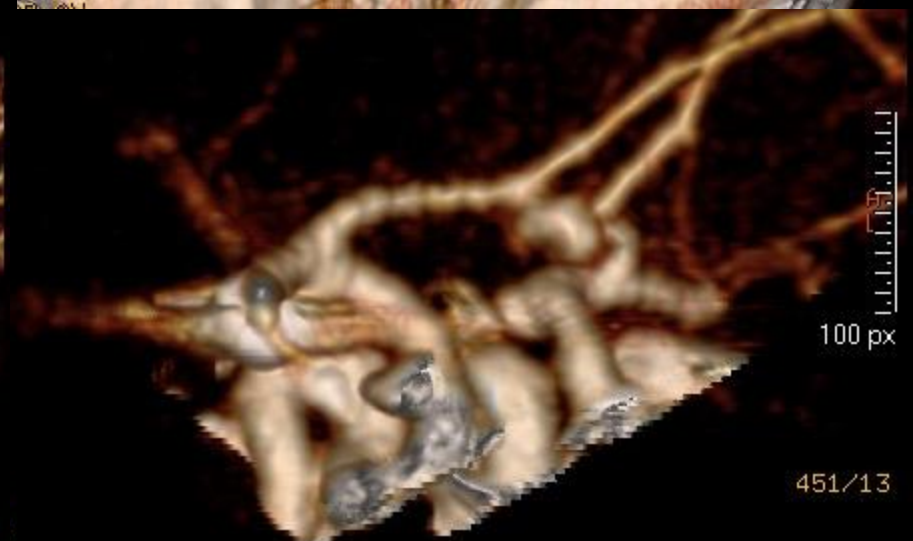
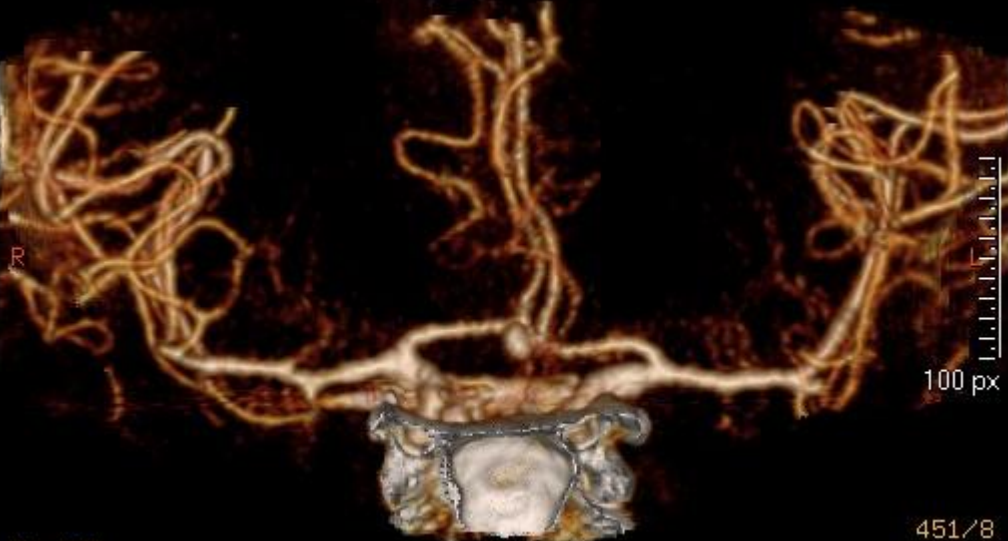
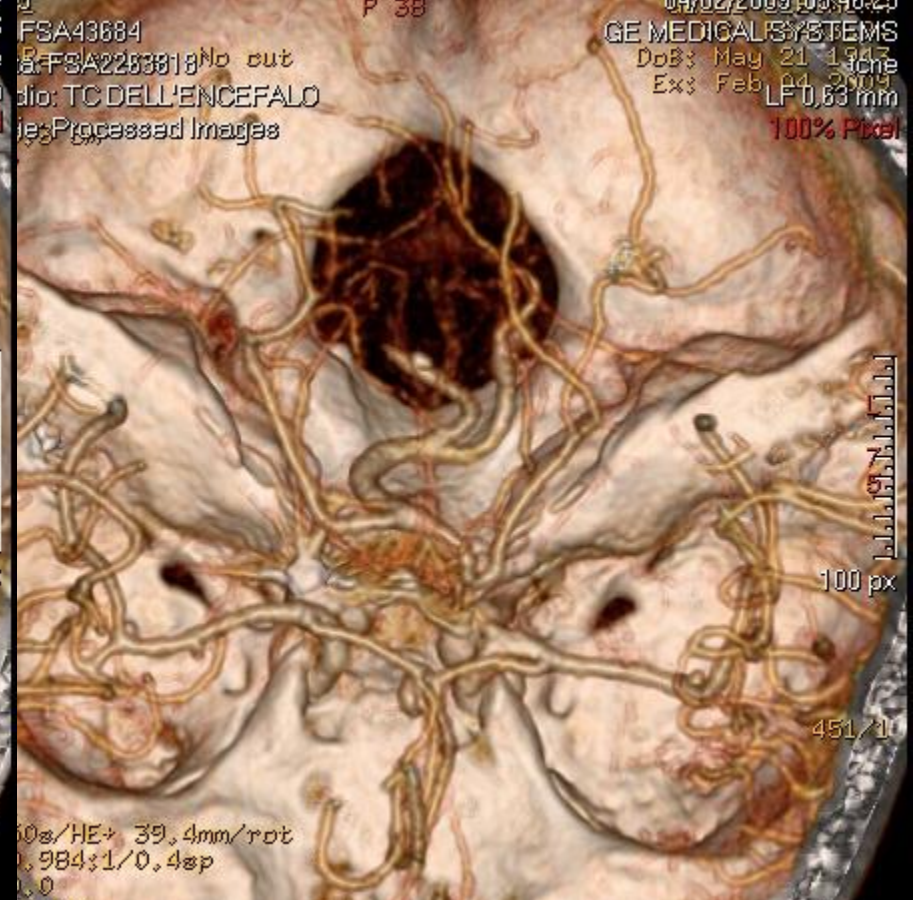
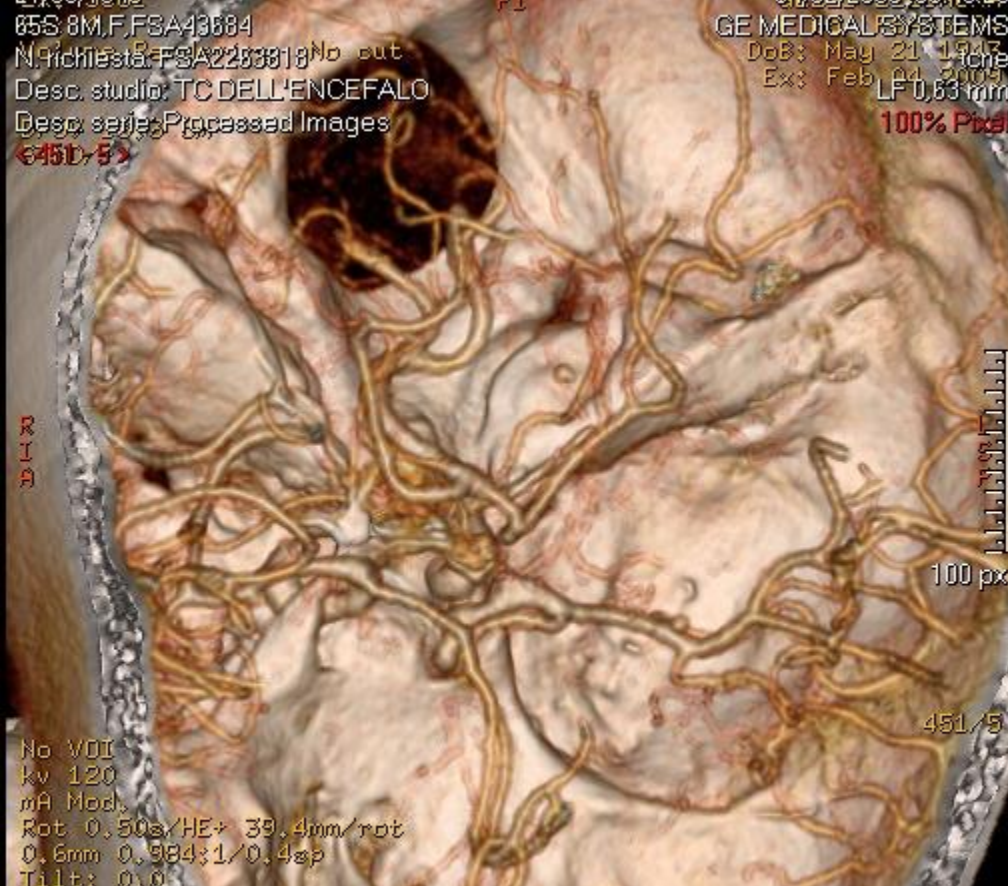


Embolizzazione con stent

(D)





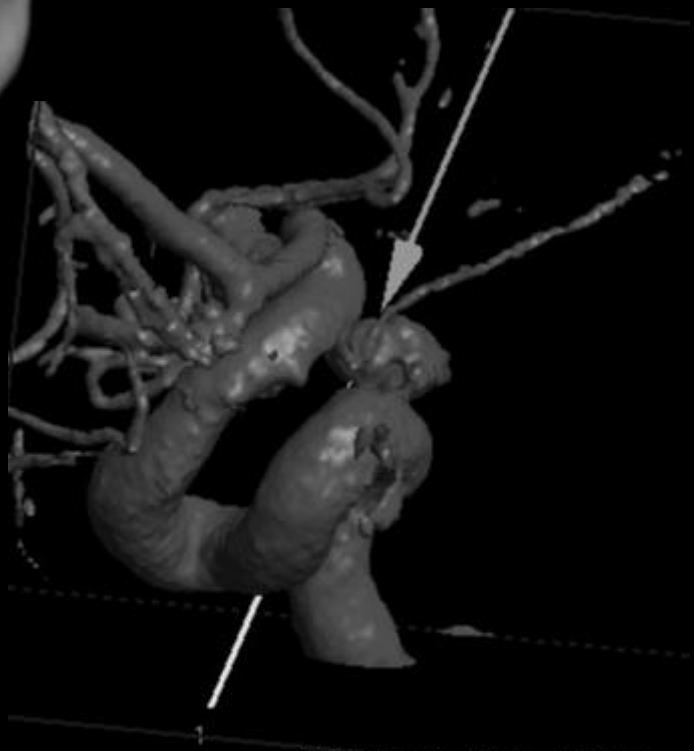
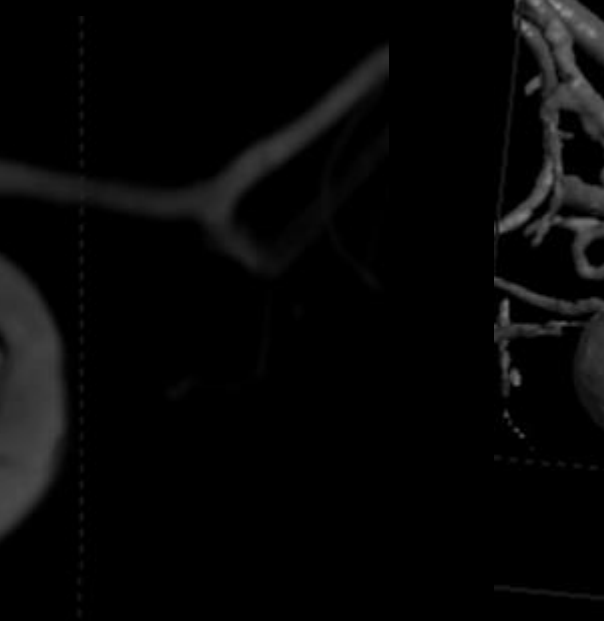
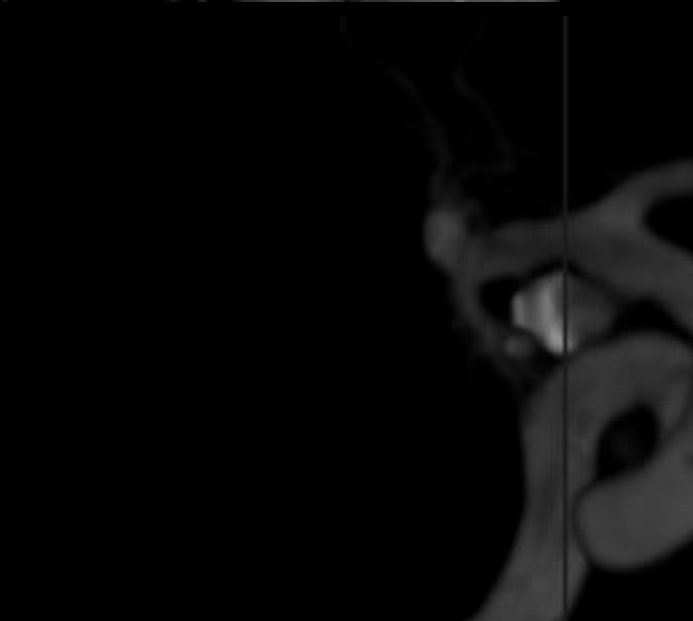
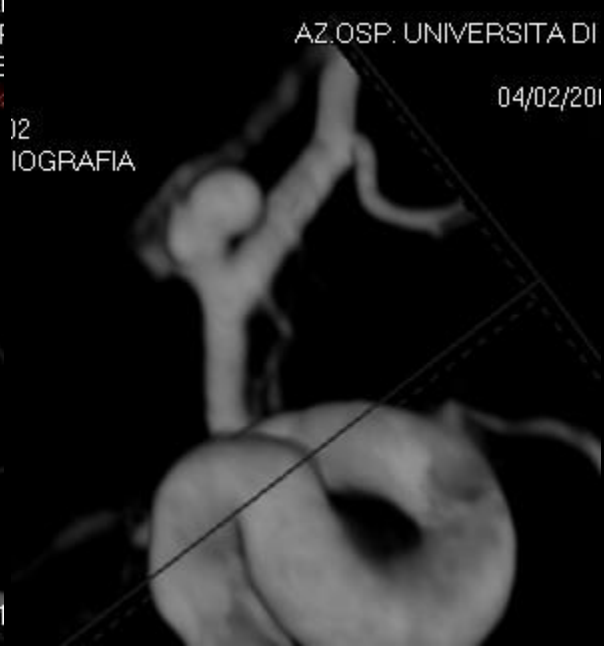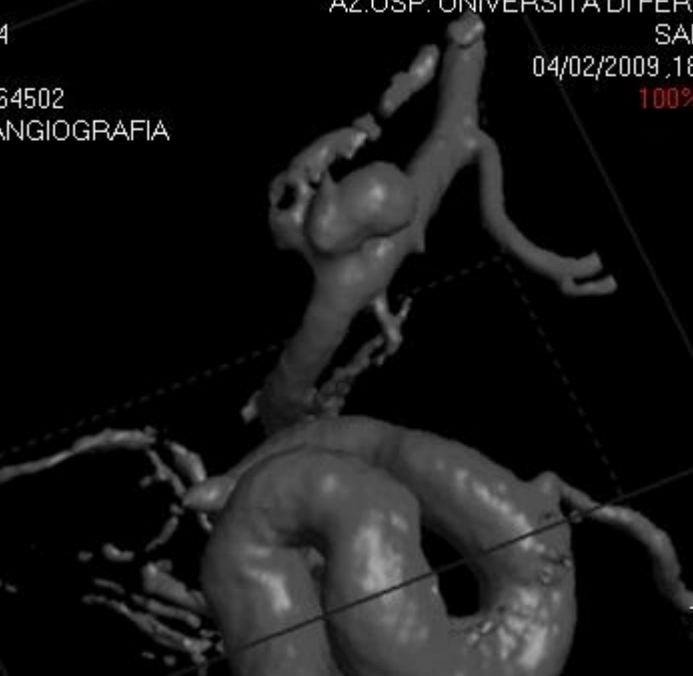4
64502
ANGIOGRAFIA

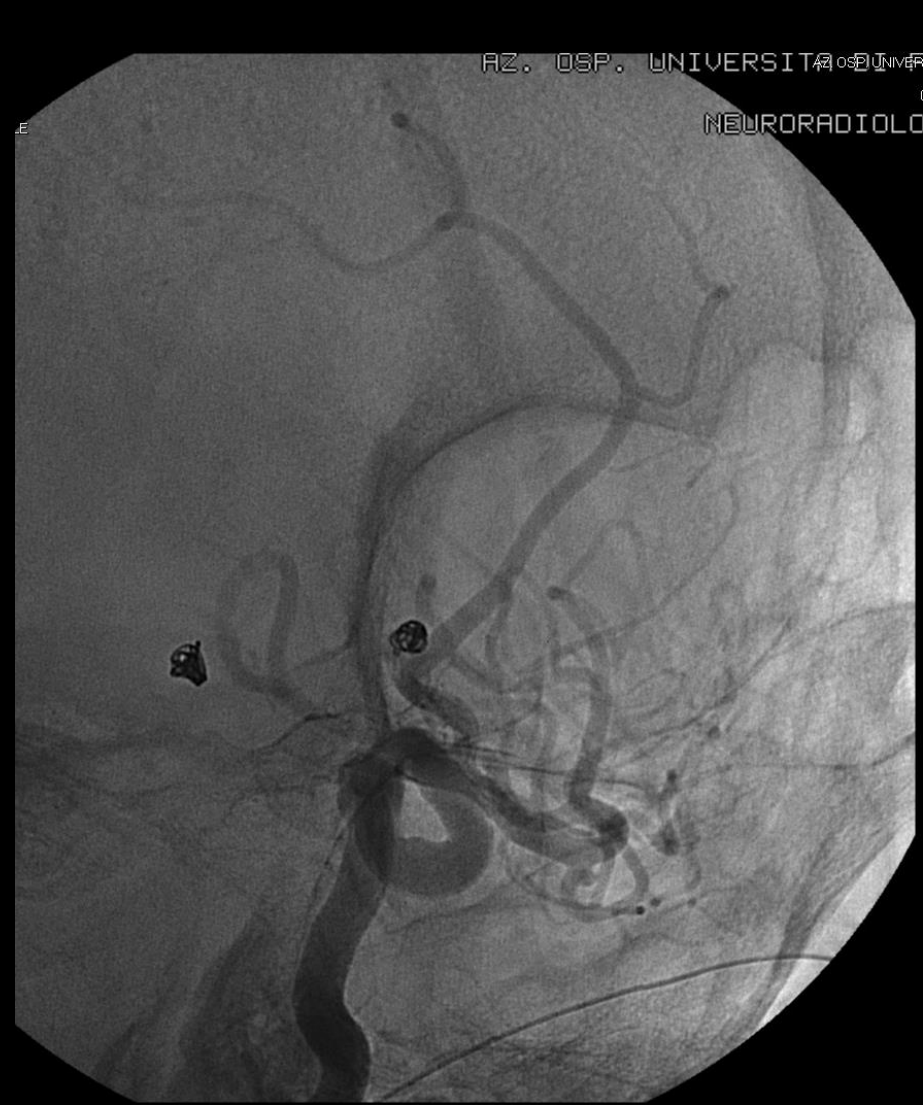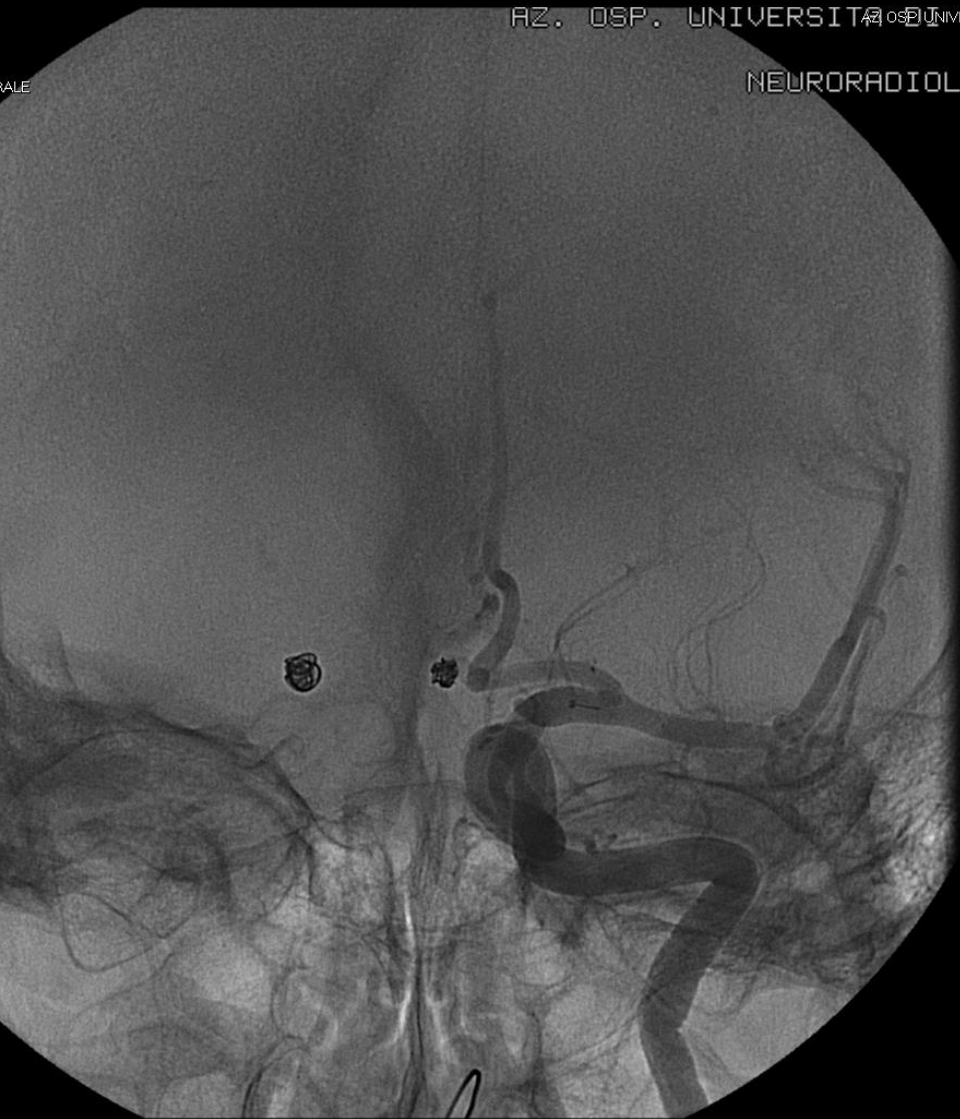
AZ. OSP. UNIVERSITA DI FERI
SAI
04/02/2009, 1E
100%

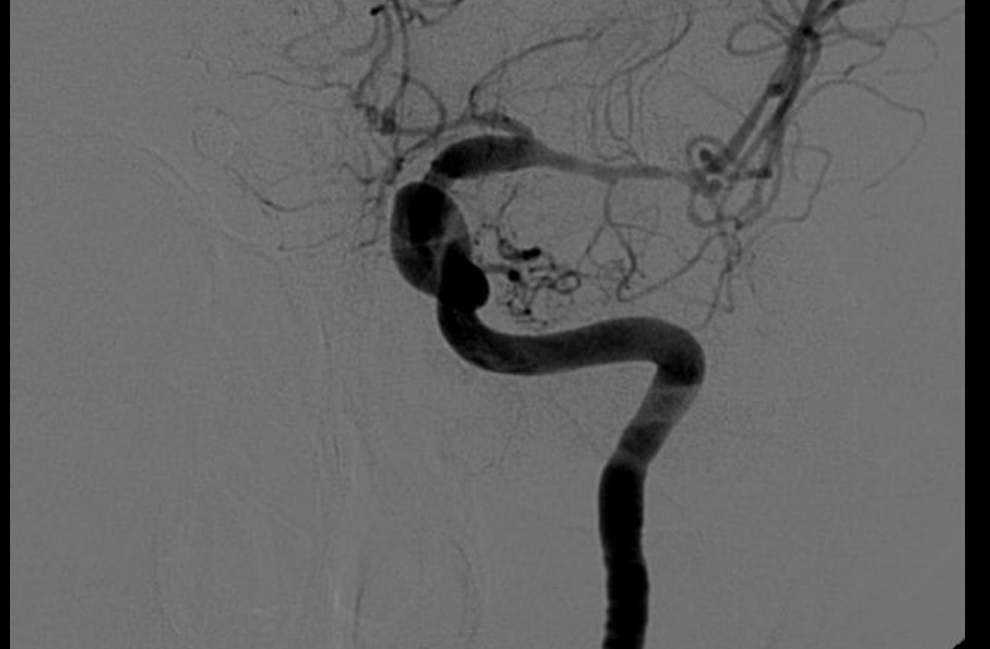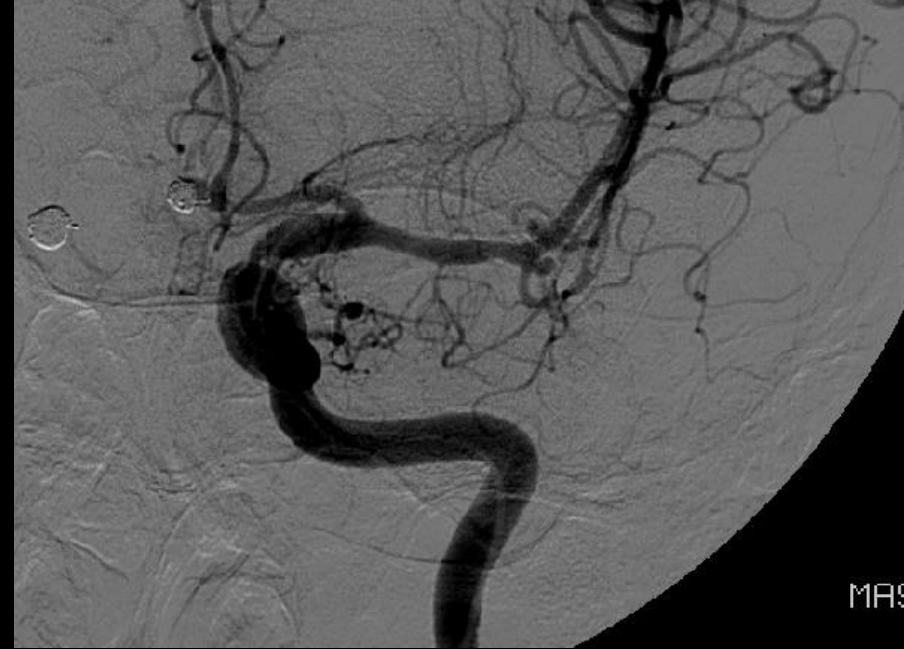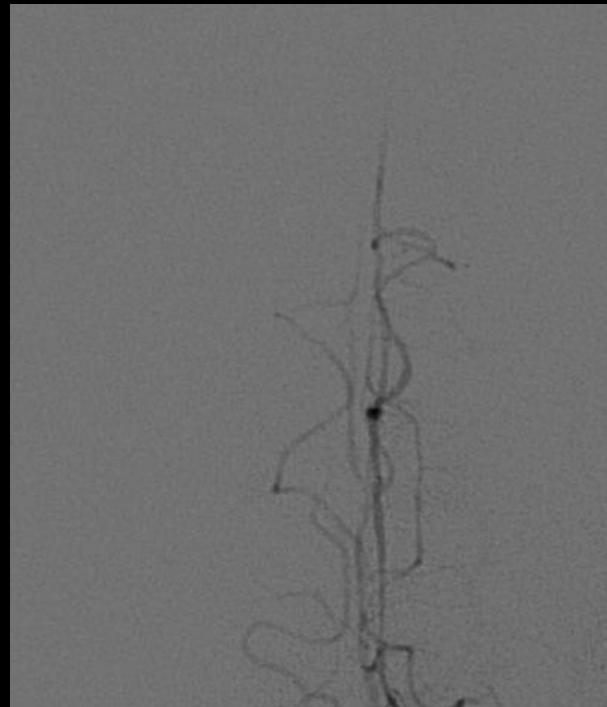
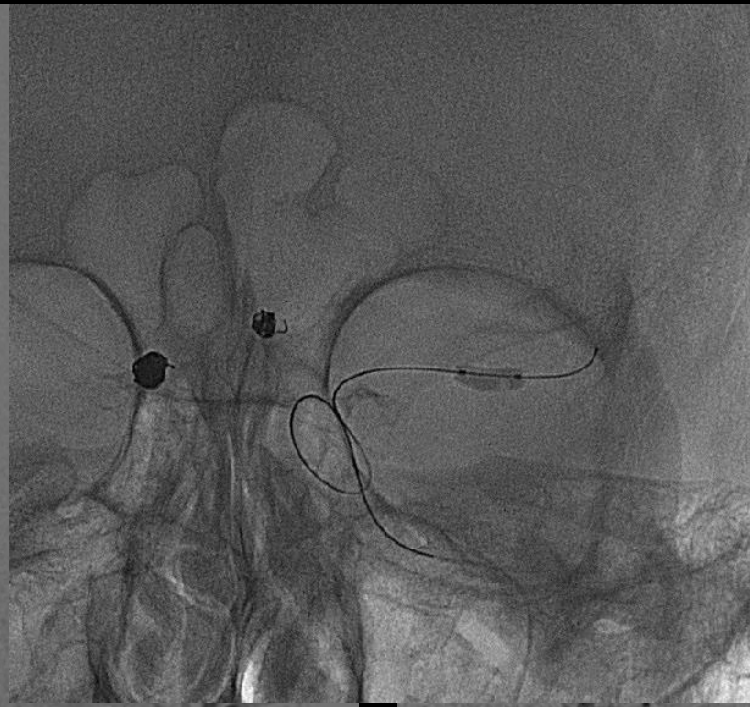
12
IOGRAFIA

AZ. OSP. UNIVERSITA DI
04/02/201

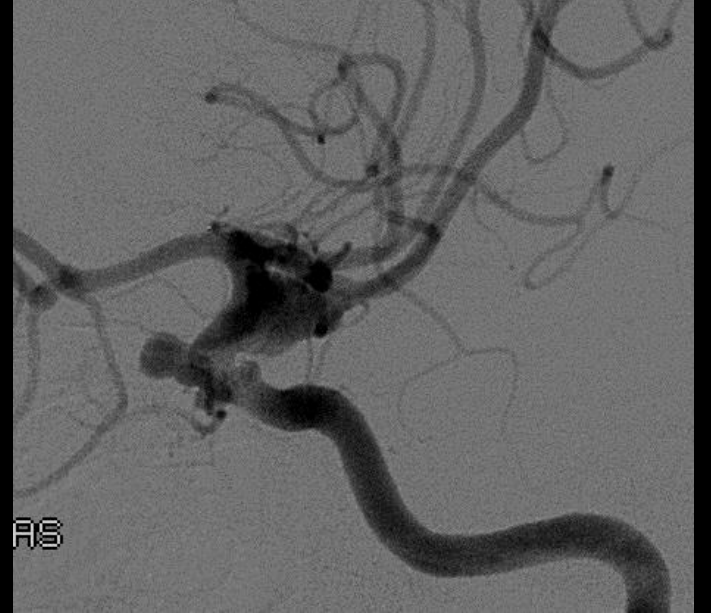
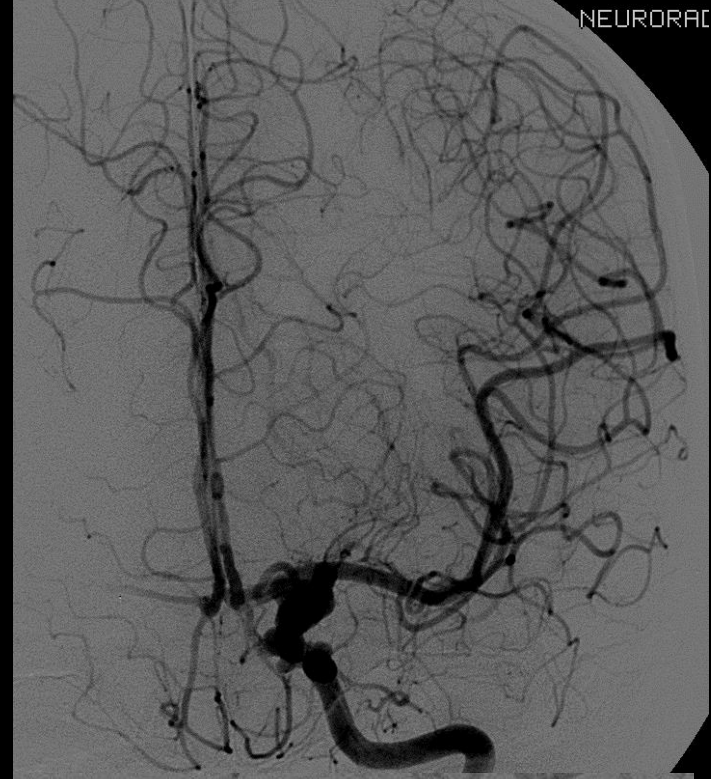
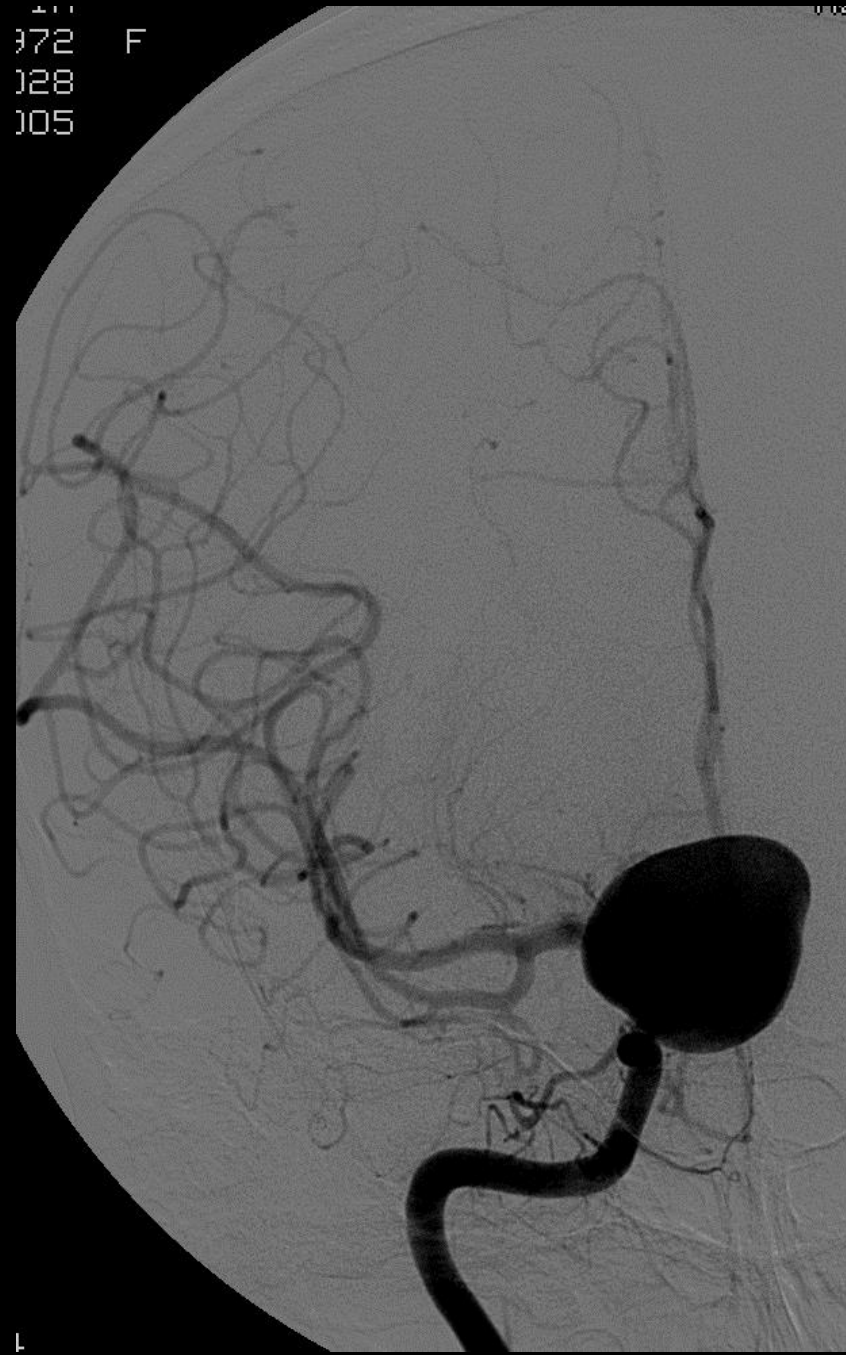Distanza misurata 1 4.33 mm





411
372 F
128
105

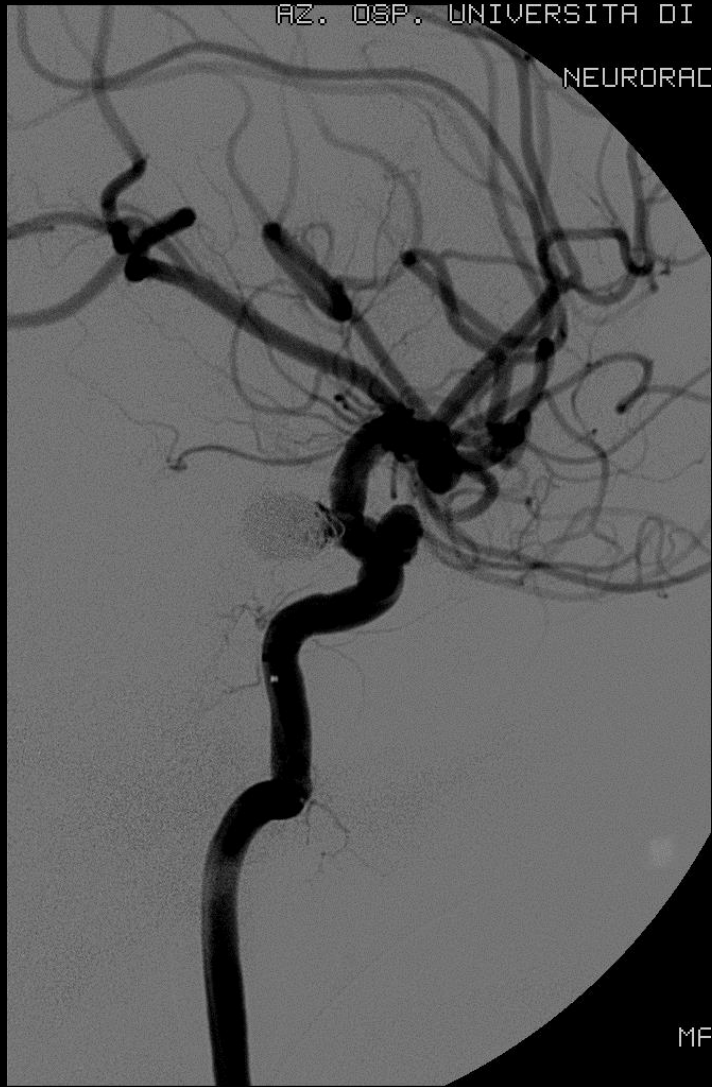

L

AS

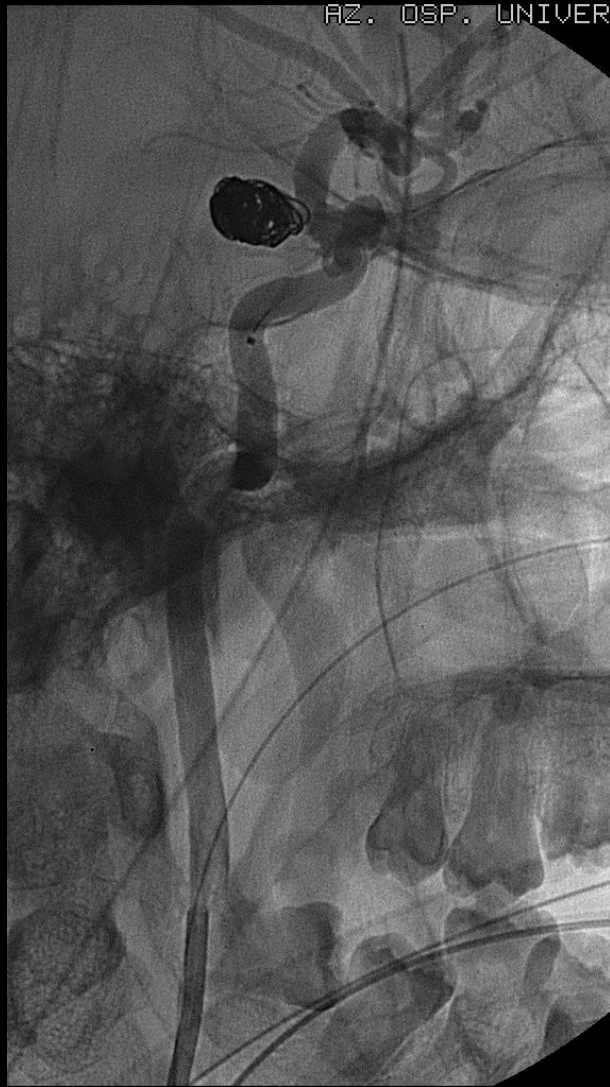
AZ. OSP. UNIVERSITA DI

NEURORAC

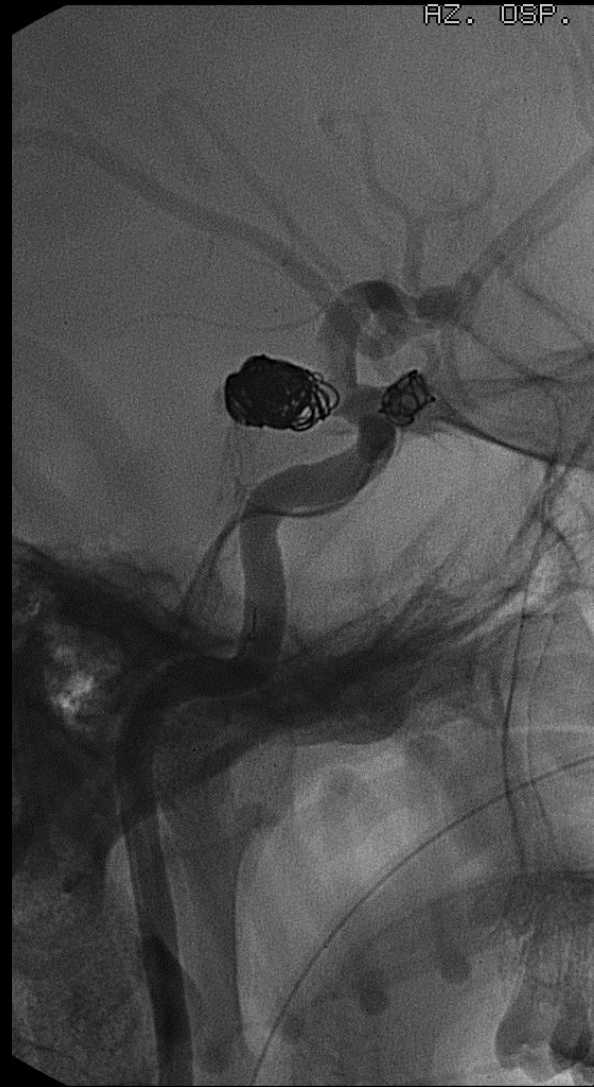

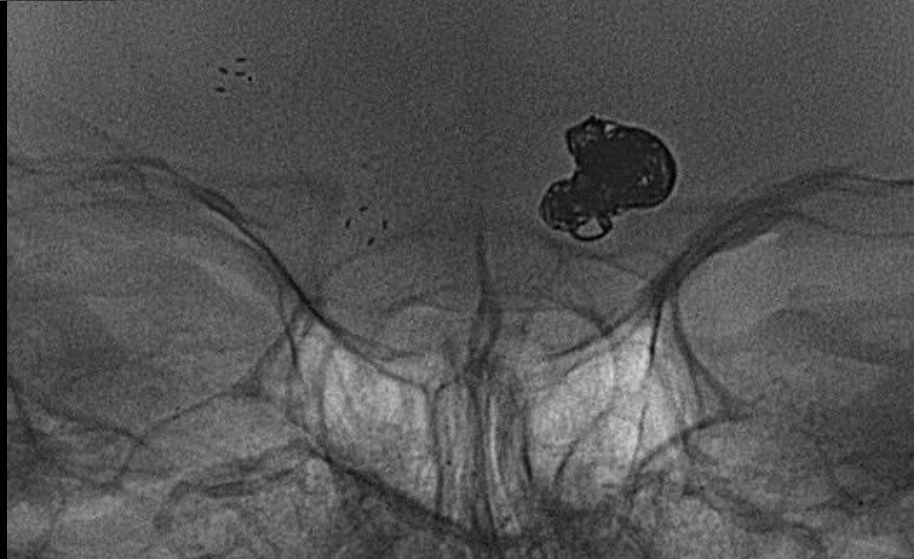

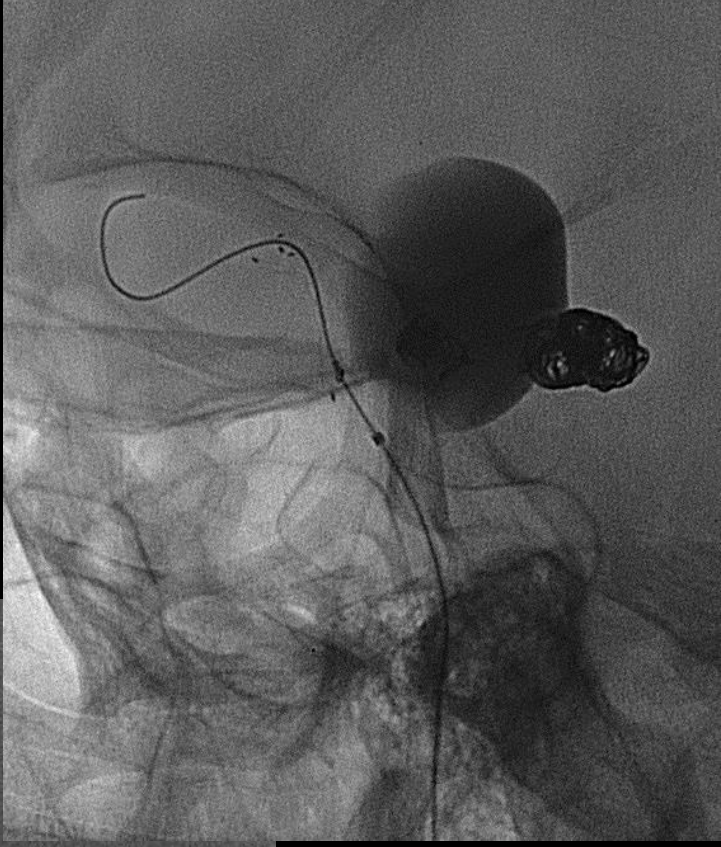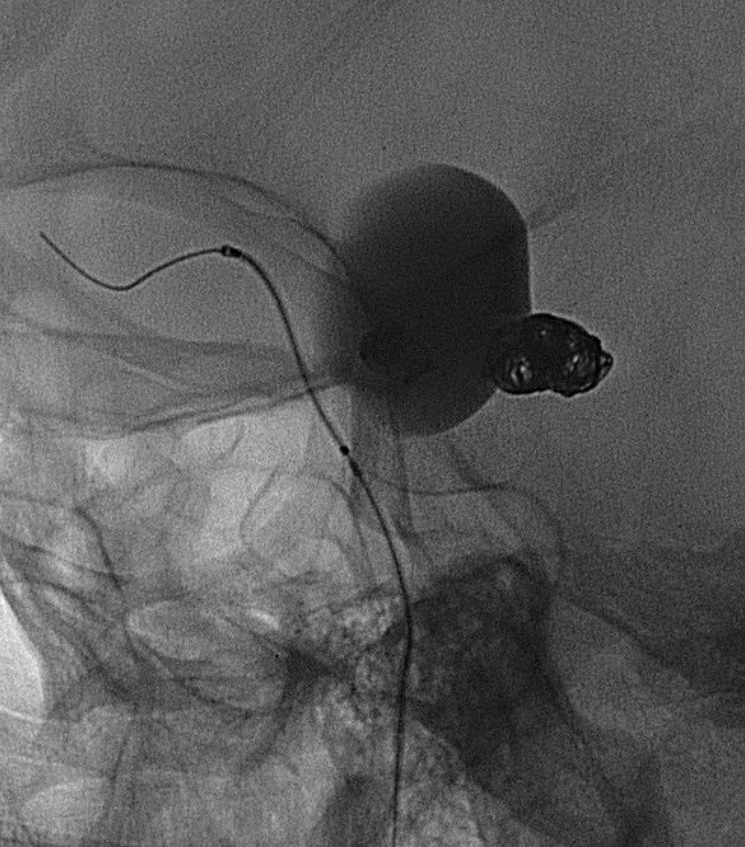MF

AZ. OSP. UNIVER

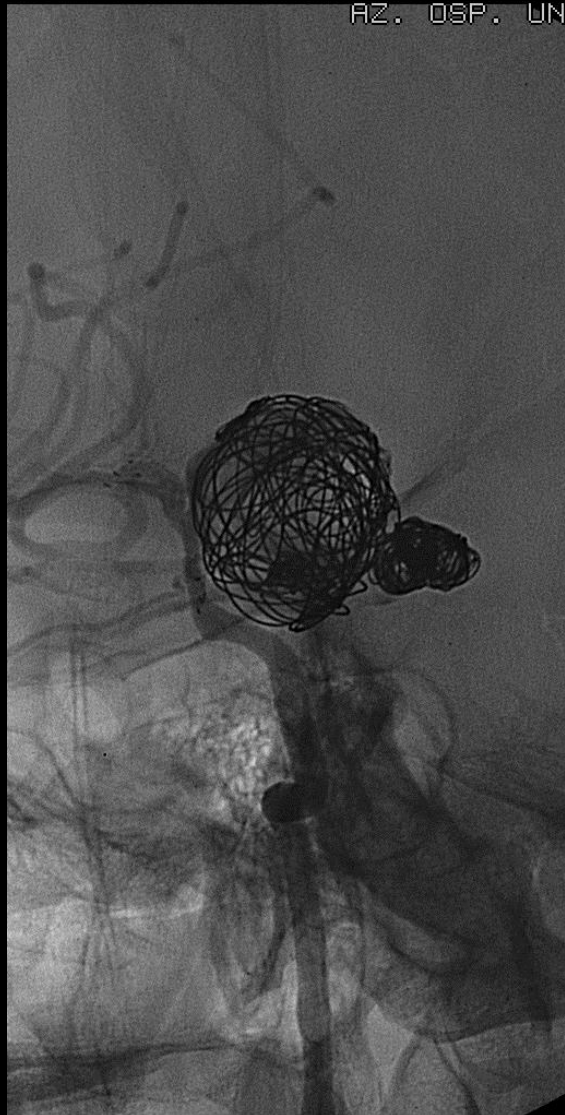


AZ. OSP.



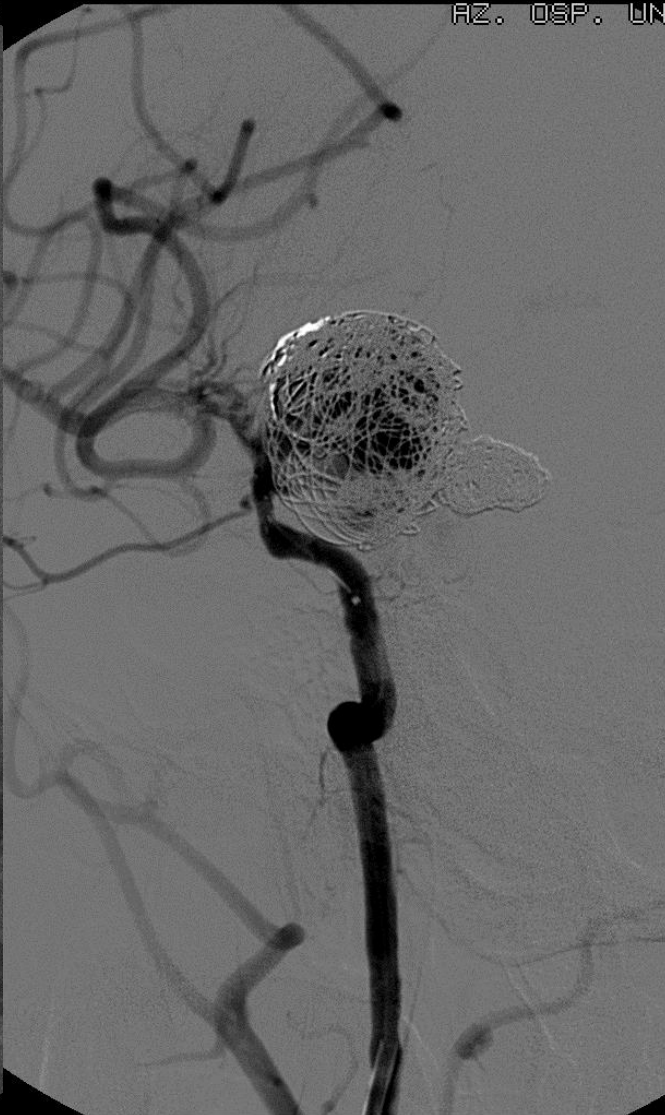

AZ. OSP. UN

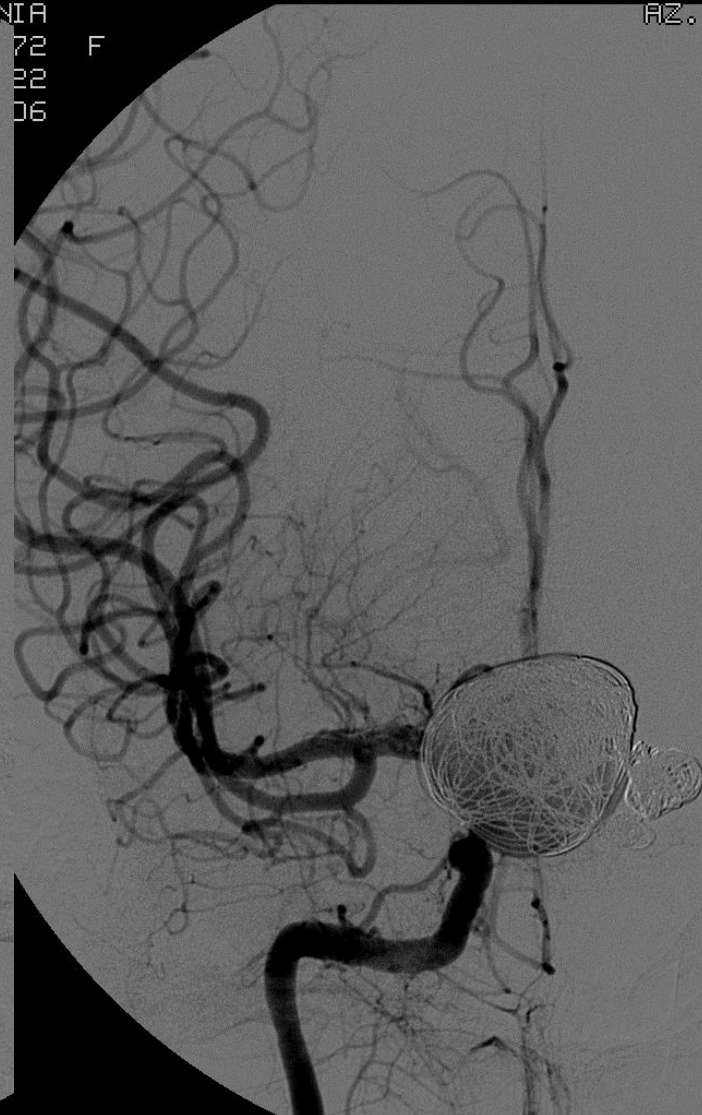


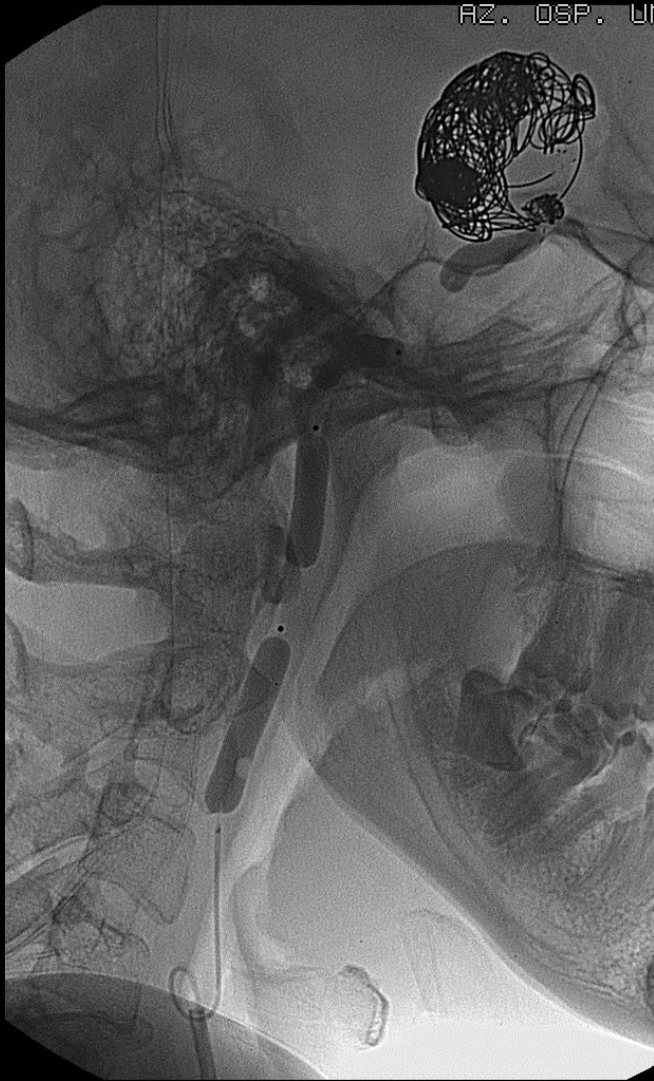AZ. OSP. UNIA

72 F
22
06



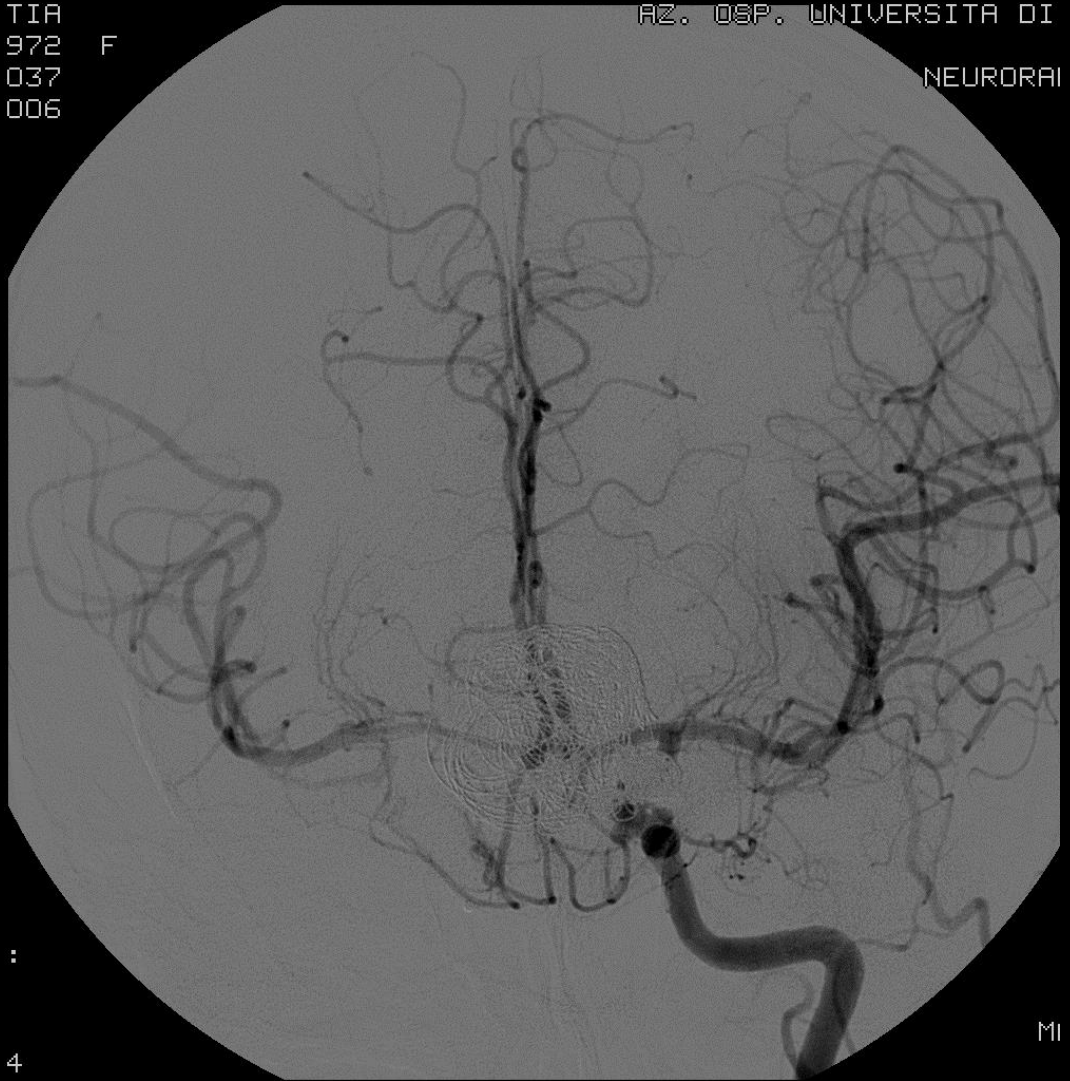
AZ.





AZ. OSP. UI

TIA
972 F
037
006



AZ. OSP. UNIVERSITA DI

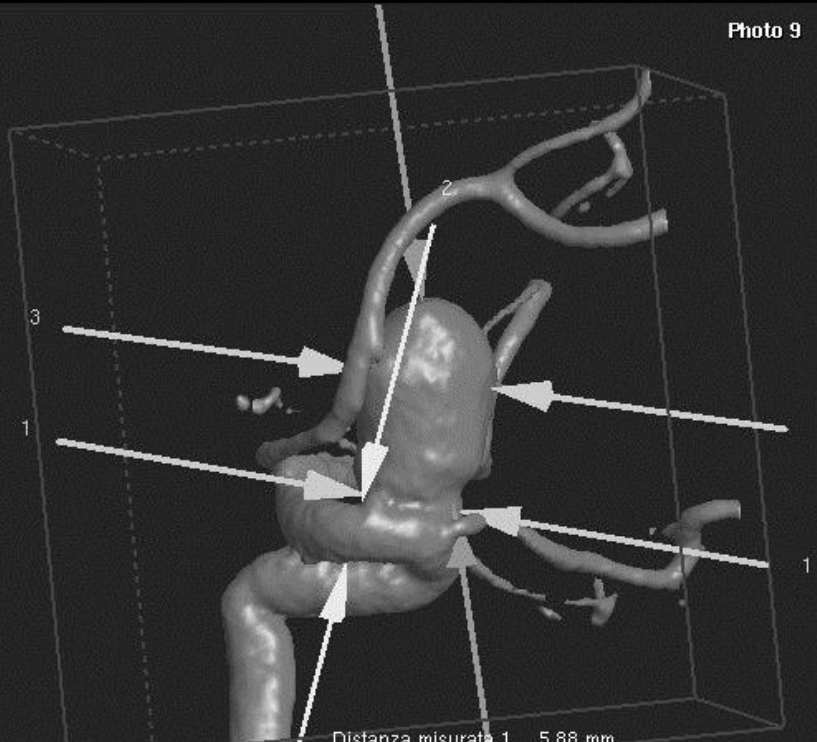
NEURORAI

:

4

M1

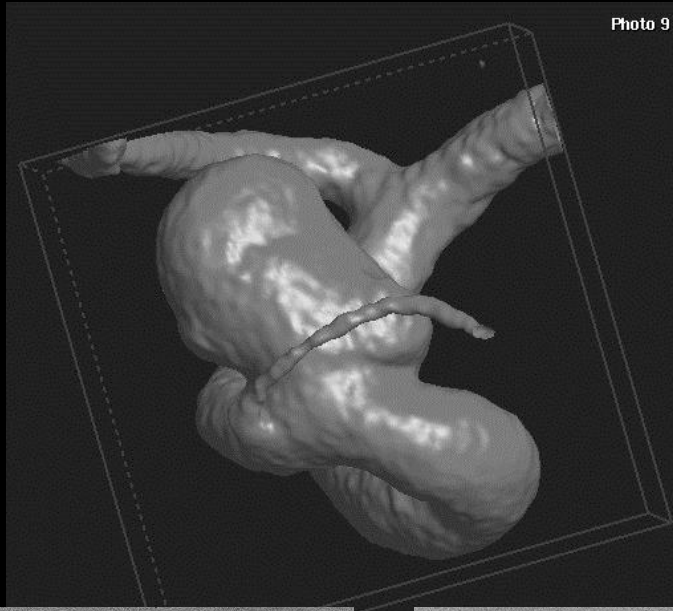
Photo 9



Distanza misurata 1 = 5.88 mm
Distanza misu
Distanza misu
Distanza misu

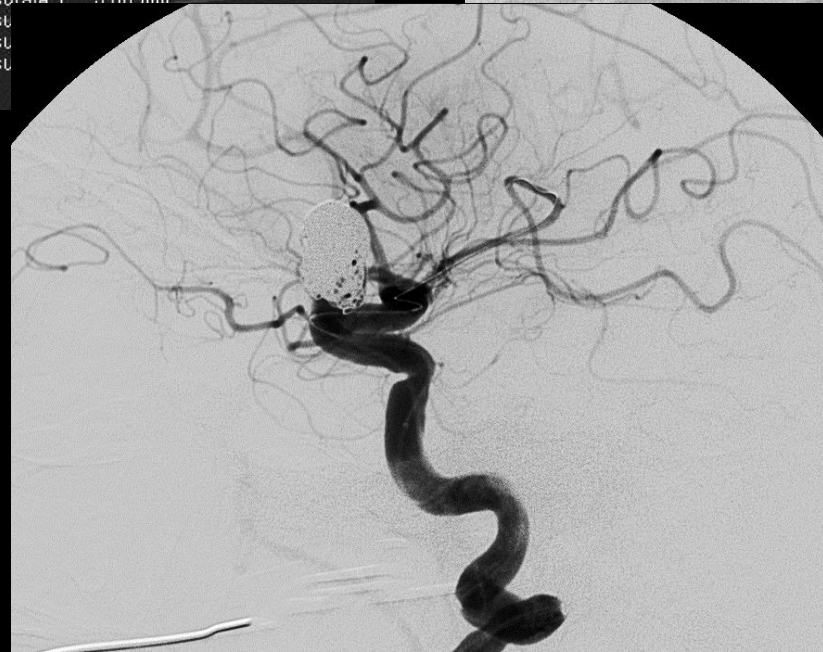
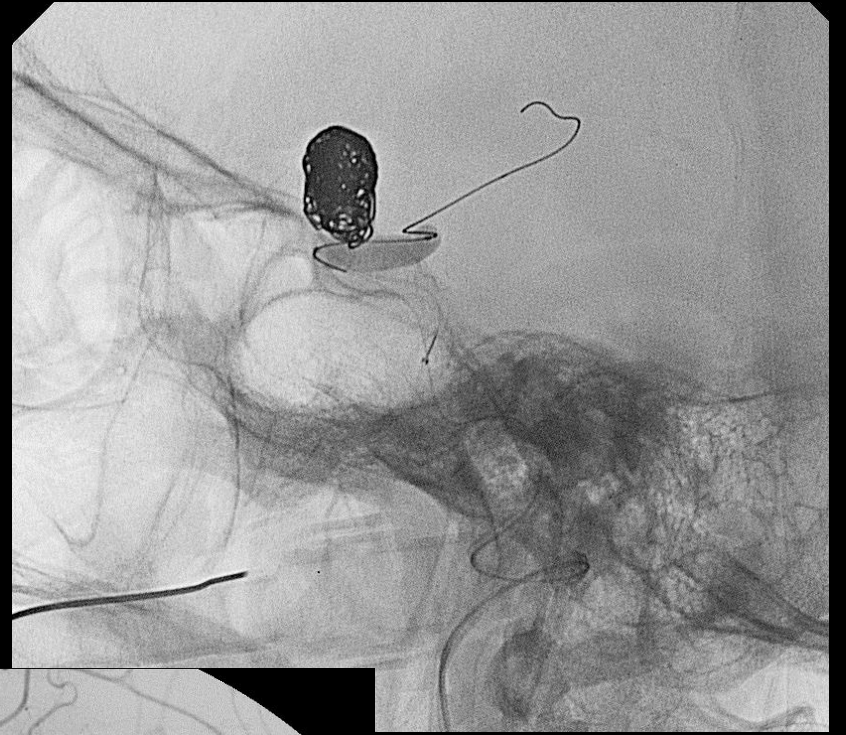
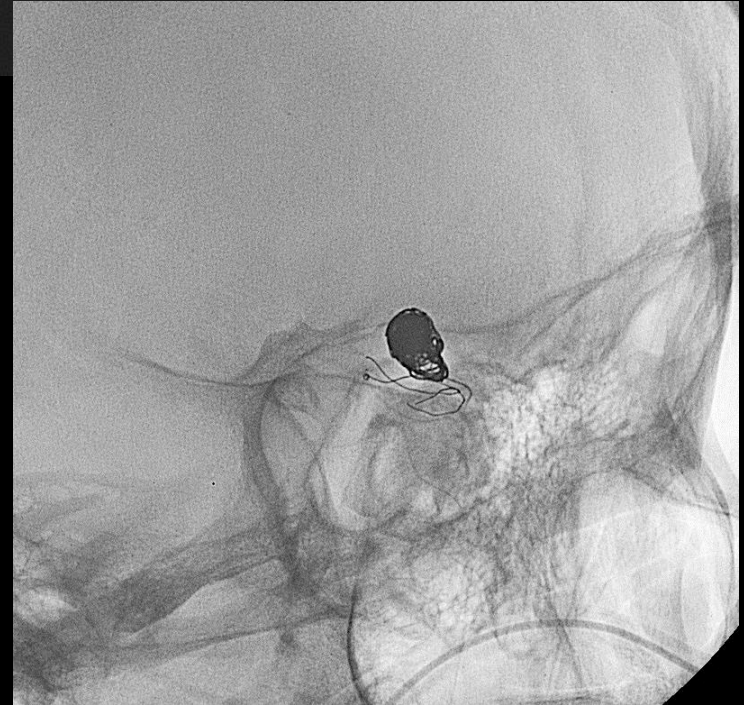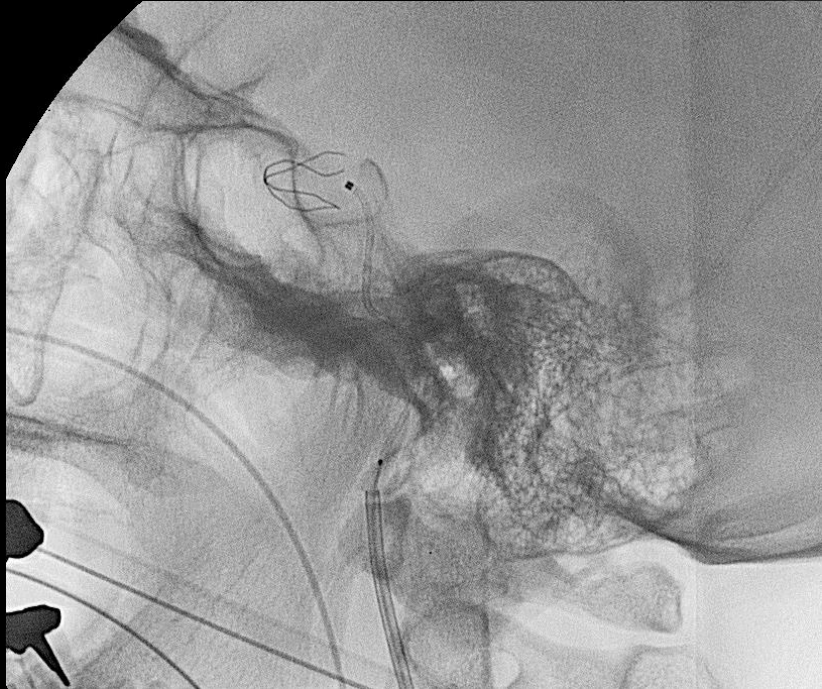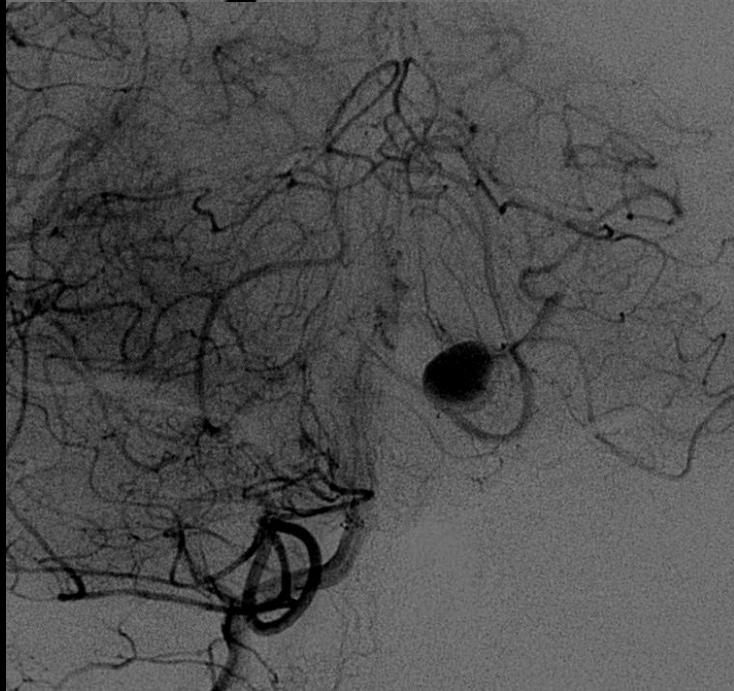
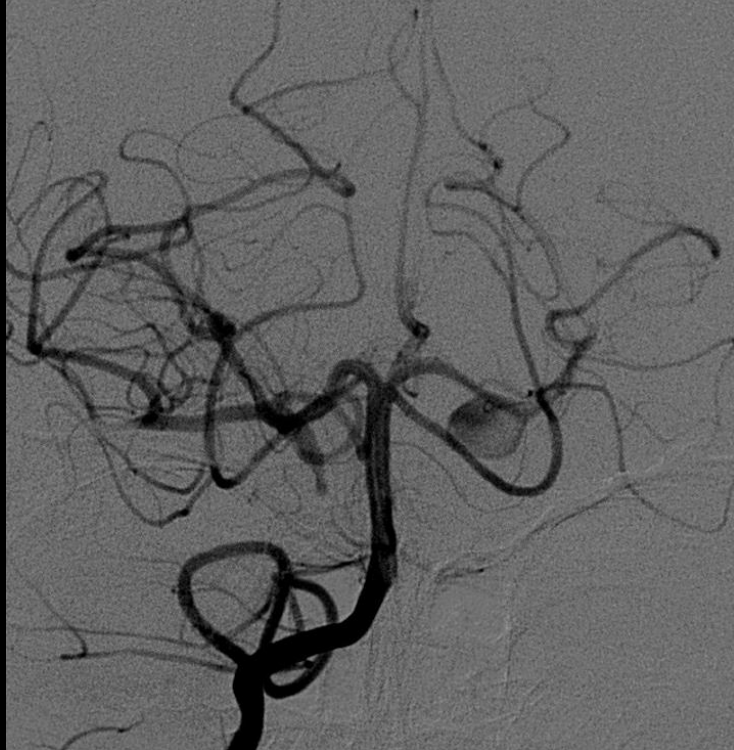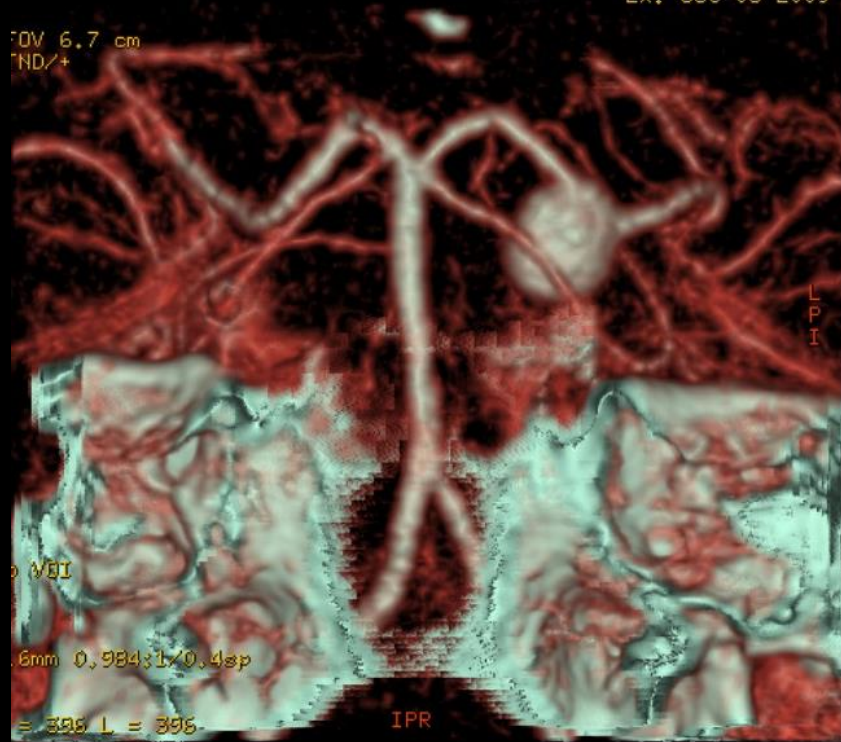Photo 9

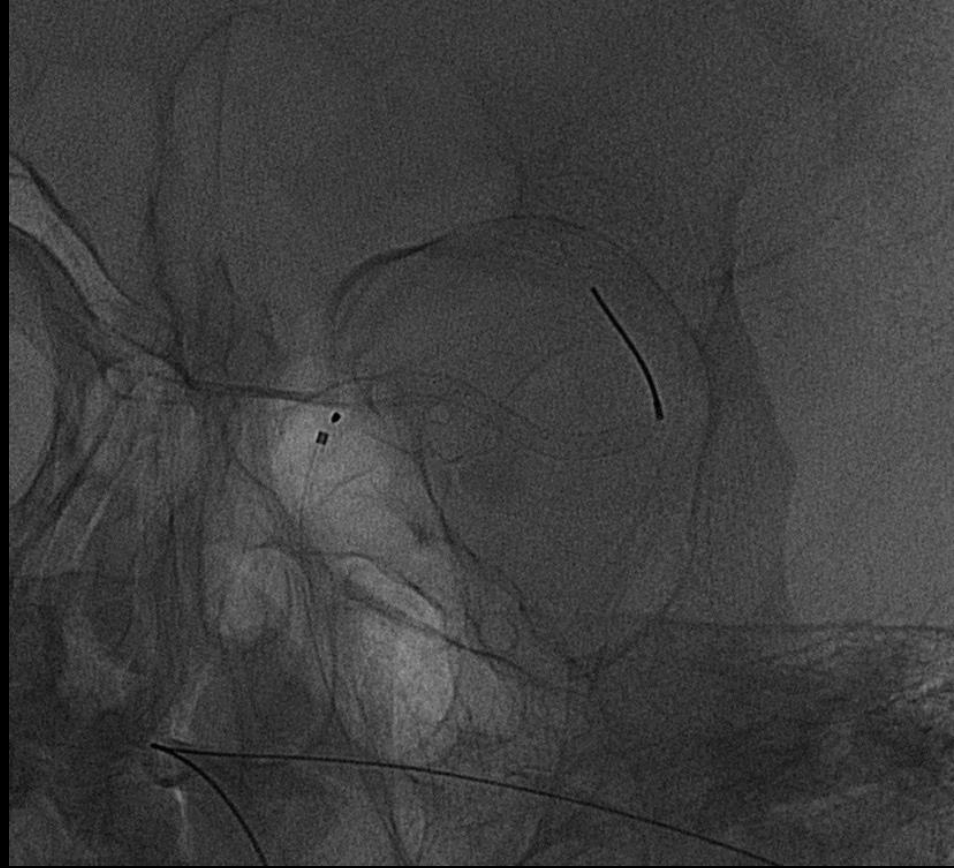
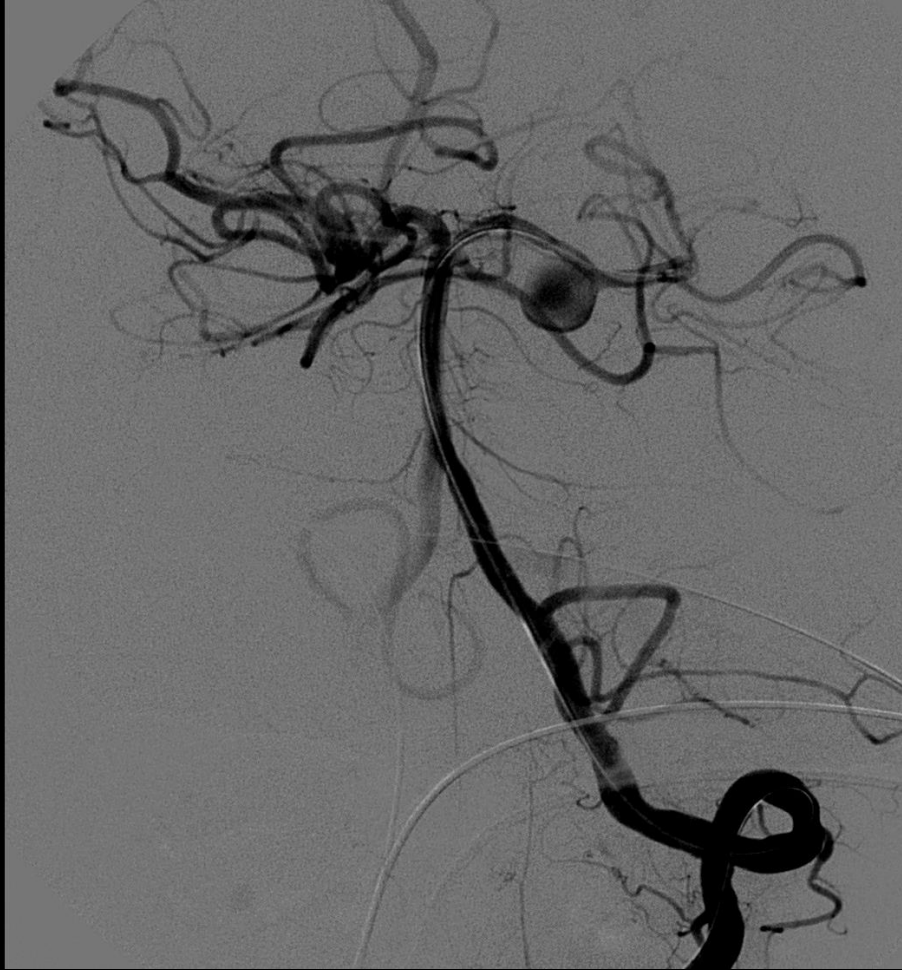

Volume Rendering No cut

Ex: Oct 05 2009

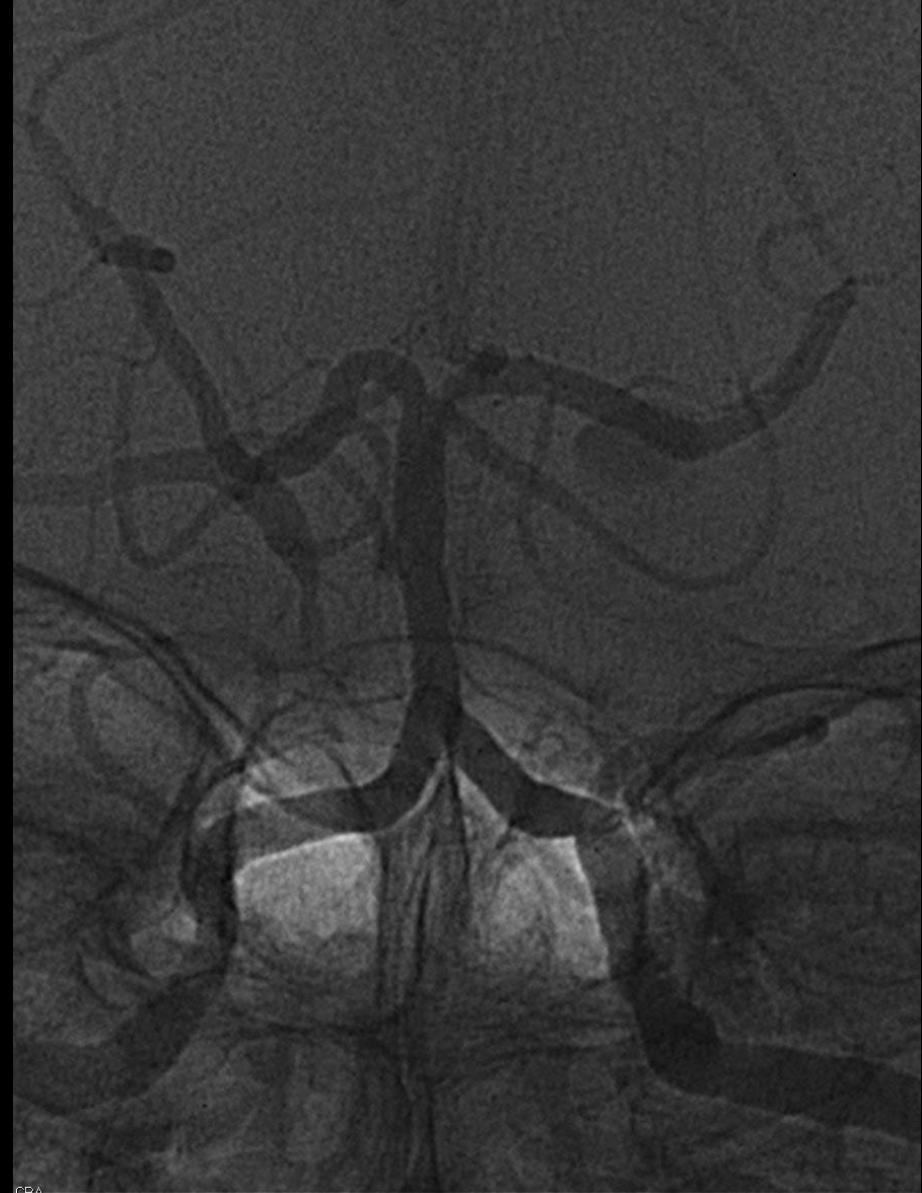
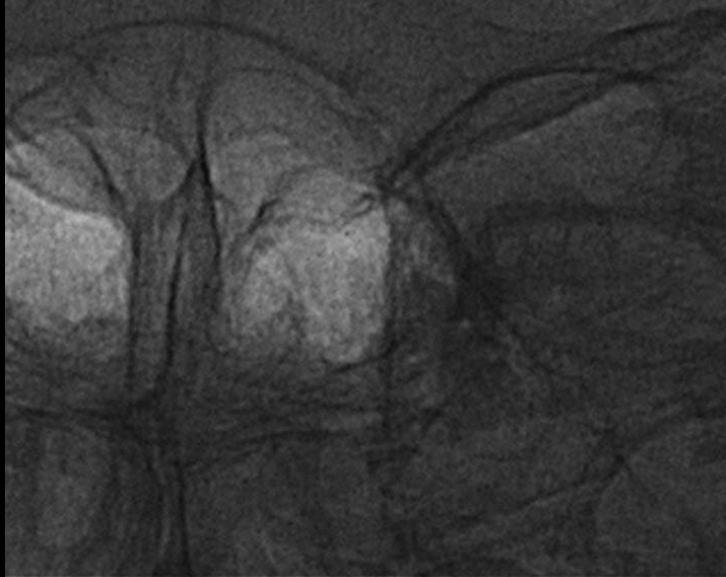
FOV 6.7 cm
TND/+





Flow diverter stent

PTO >



SENZA EBONICO CONTRASTING No cut

Ex: Jan 19 2010

DFOV 14.3 cm
STND/+

L
P

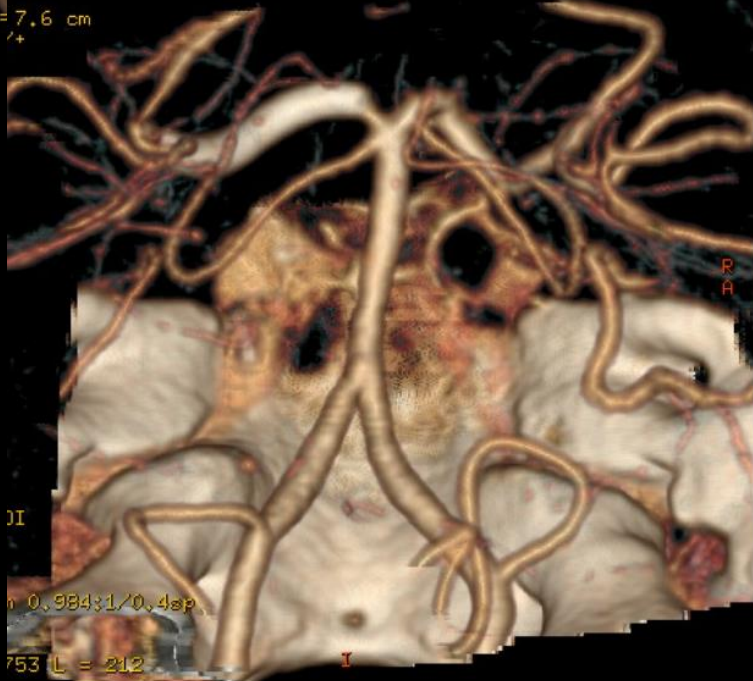
R
P

No VOI

0,6mm 0,984;1/0,4sp

W = 7.6 cm
/+

Ex: Jan 19 2010



II

0,6mm 0,984;1/0,4sp

W = 753 L = 212

I

W 7.6 cm
ID/+

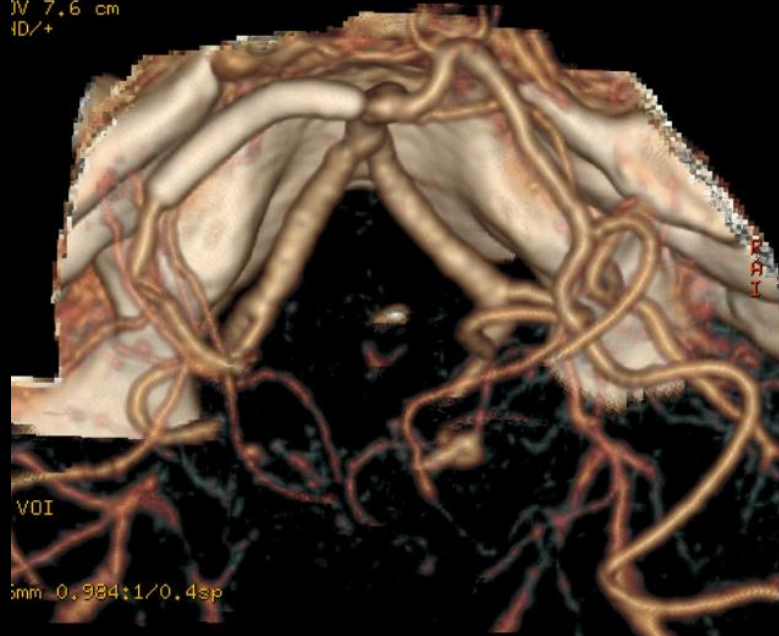VOI

0,6mm 0,984;1/0,4sp

W = 753 L = 212

PRI

DFOV 7.6 cm
STND/+



L
P
I

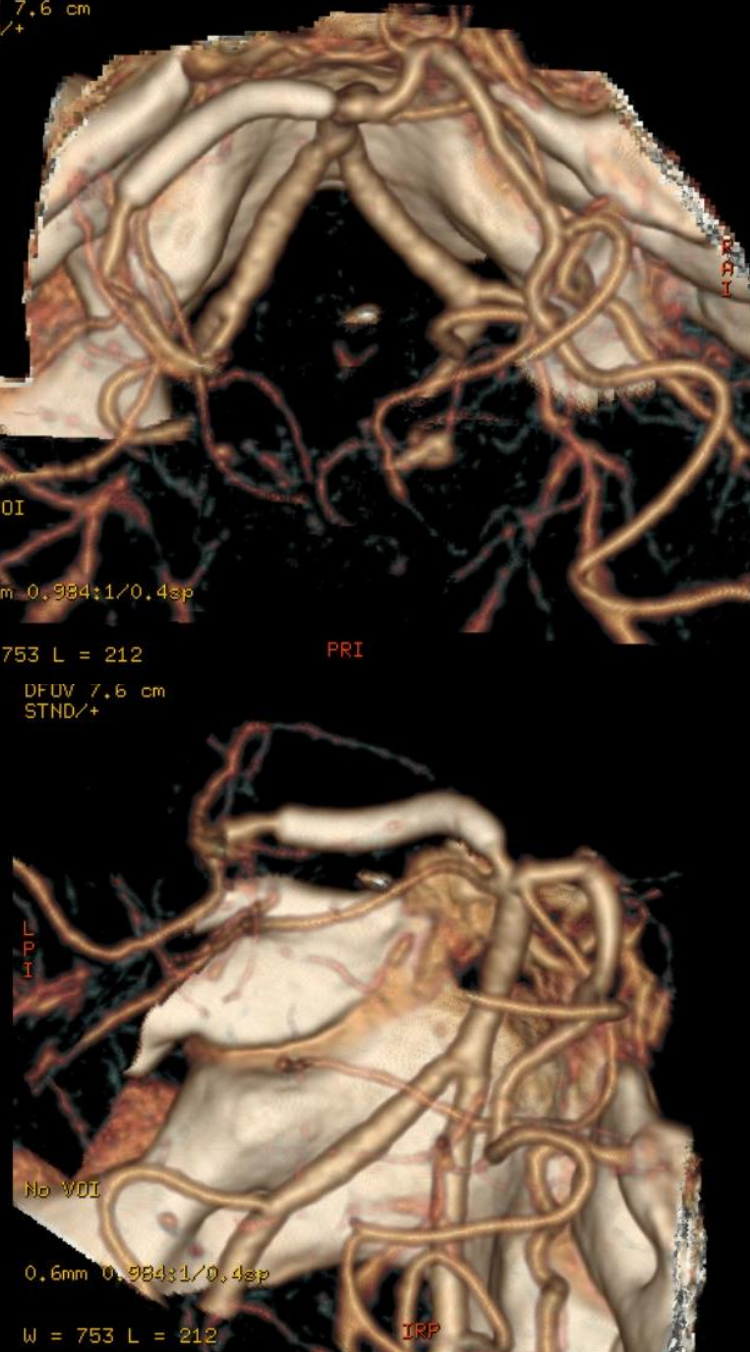L
P
I

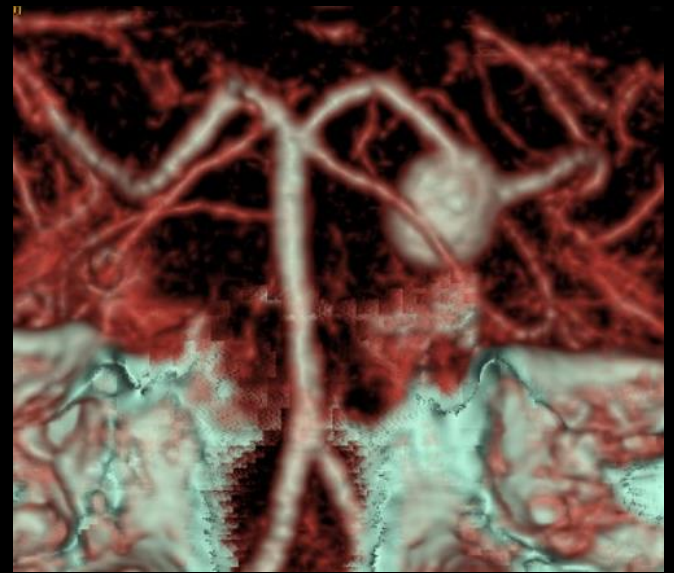
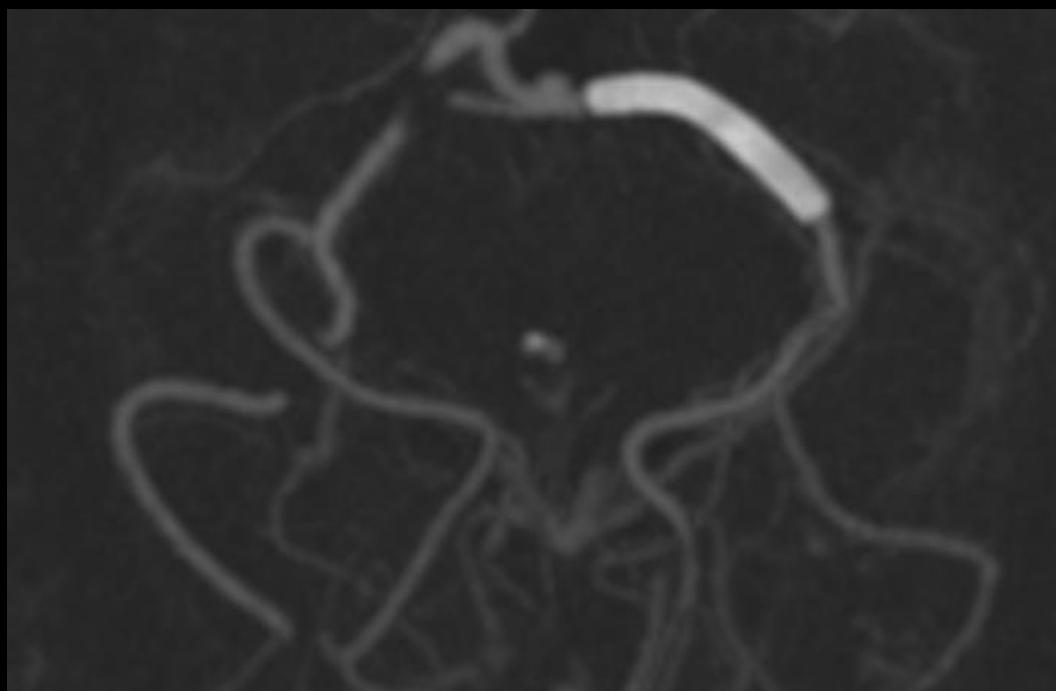
No VOI

0,6mm 0,984;1/0,4sp

W = 753 L = 212

IRP

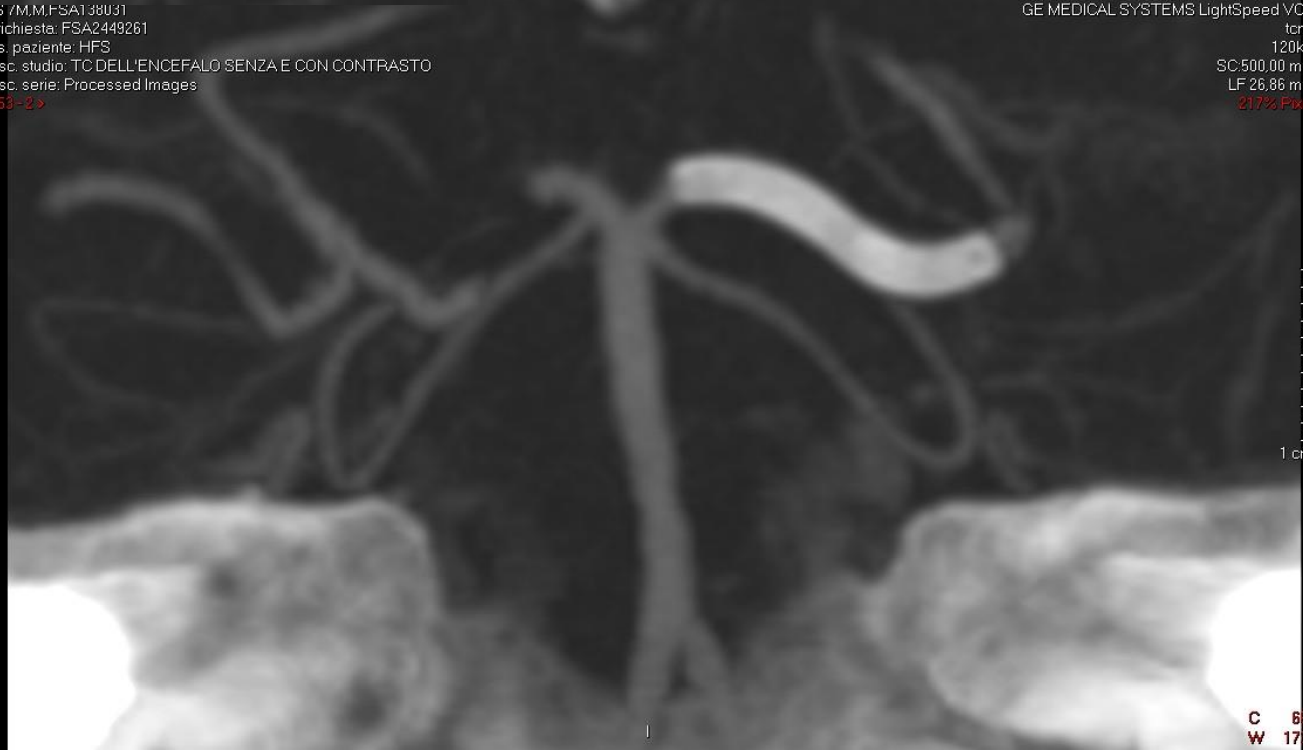



b5S VM.M.FSA138031
N. richiesta: FSA2449261
Pos. paziente: HFS
Desc. studio: TC DELL'ENCEFALO SENZA E CON CONTRASTO
Desc. serie: Processed Images
< 453-2 >

OSPEDALE S. ANNA FERRARA
19/01/2010 .17.47.01
GE MEDICAL SYSTEMS LightSpeed VCT
tnc
120kV
SC:500,00 mm
LF 26.86 mm
217% Pixel

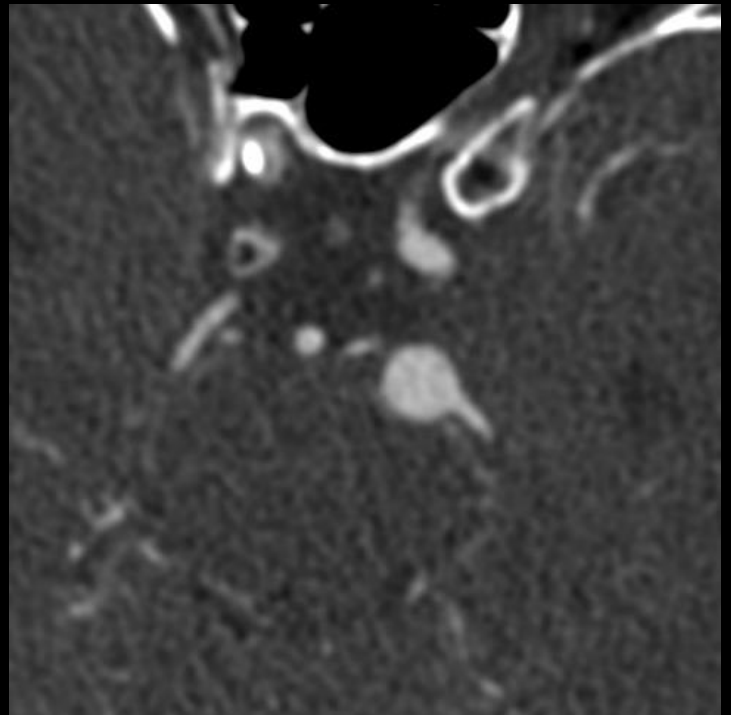
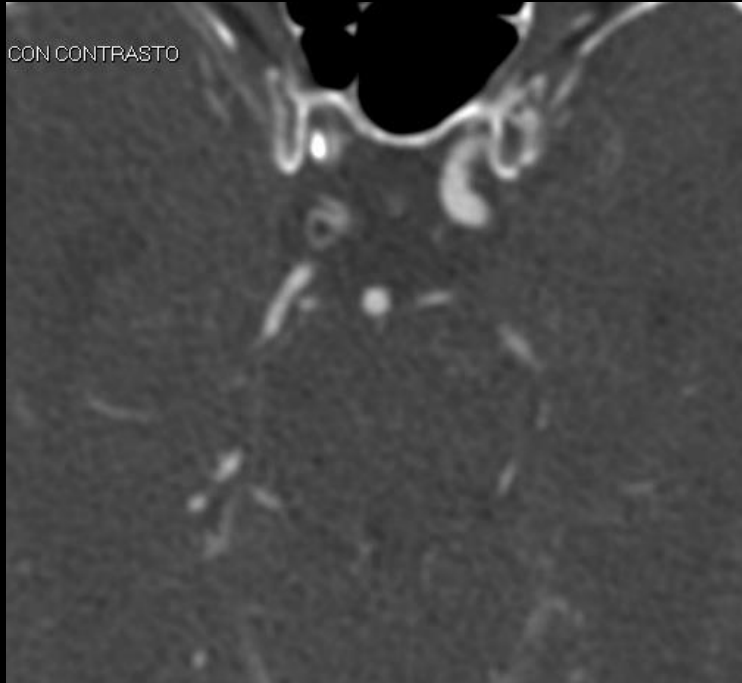
R



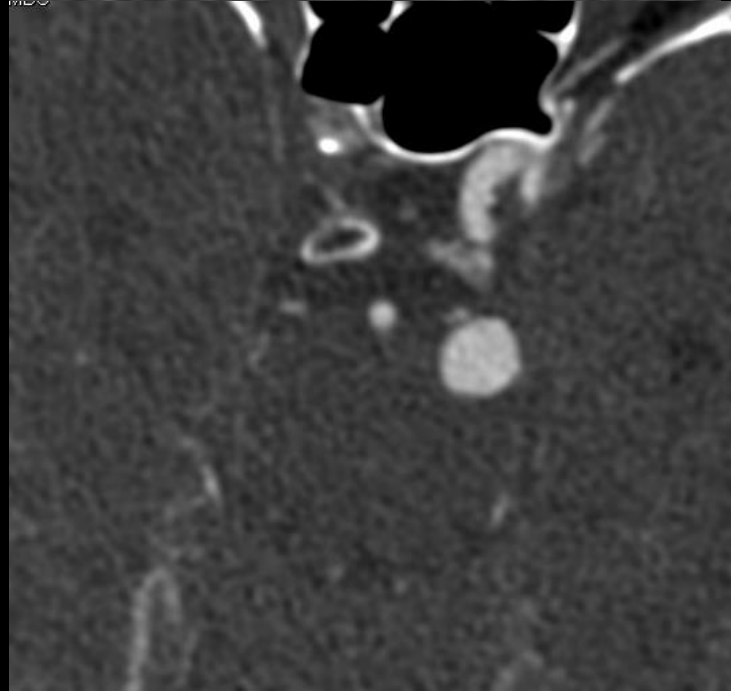
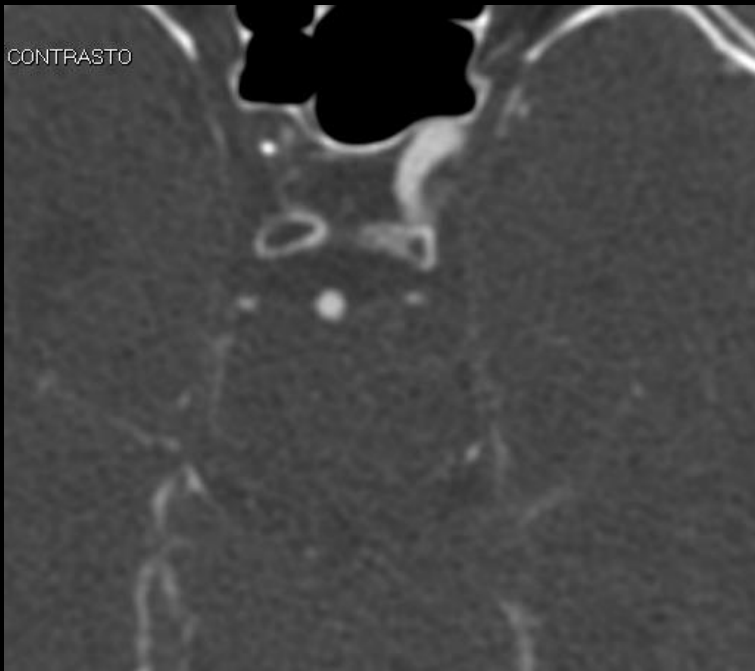
1 cm

C 61
W 17

CON CONTRASTO



CONTRASTO



ICTUS ISCHEMICO

ICTUS ISCHEMICO

In Italia 10-12% di tutti i decessi/anno

3° causa di morte dopo le malattie cardiovascolari e neoplasie

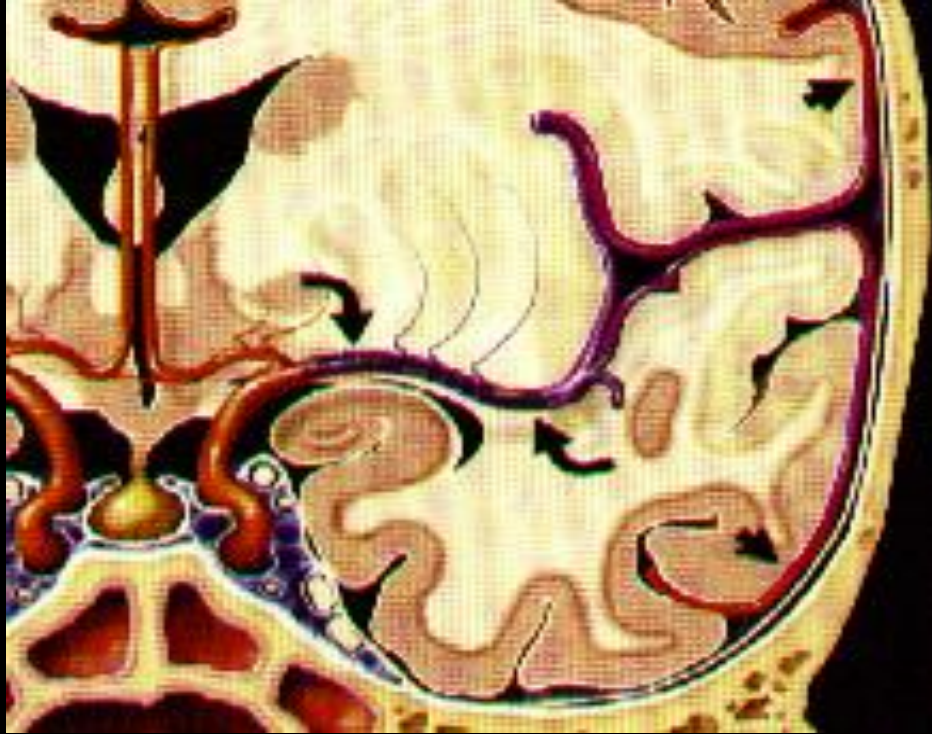
Negli ultimi anni incidenza media 2.5/100.000 abitanti

10% muore entro i primi 30 gg

50% dei sopravvissuti destinato alla disabilità



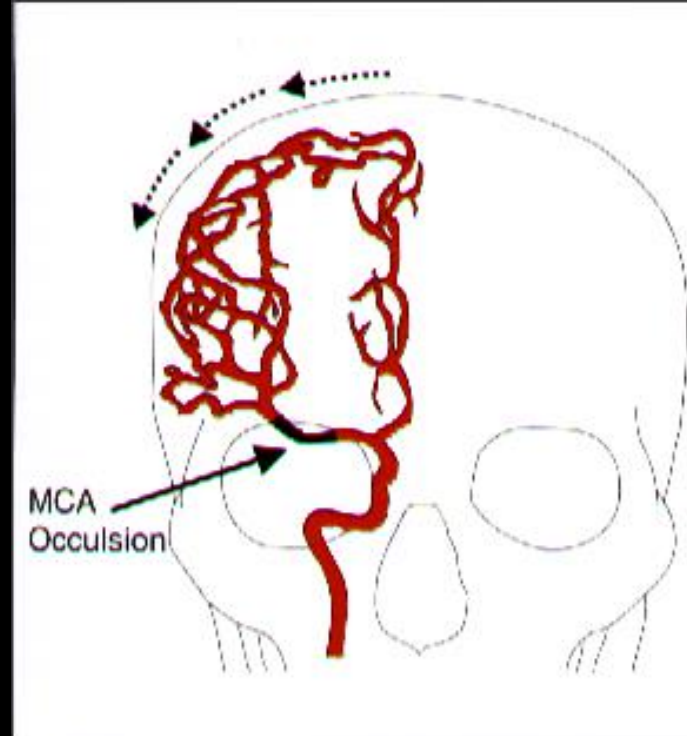
L'ISCHEMIA CEREBRALE



L'**ischemia cerebrale** è una condizione fisiopatologica determinata da una **riduzione del flusso ematico cerebrale** o **ipoperfusione** a livello di una zona di tessuto nervoso



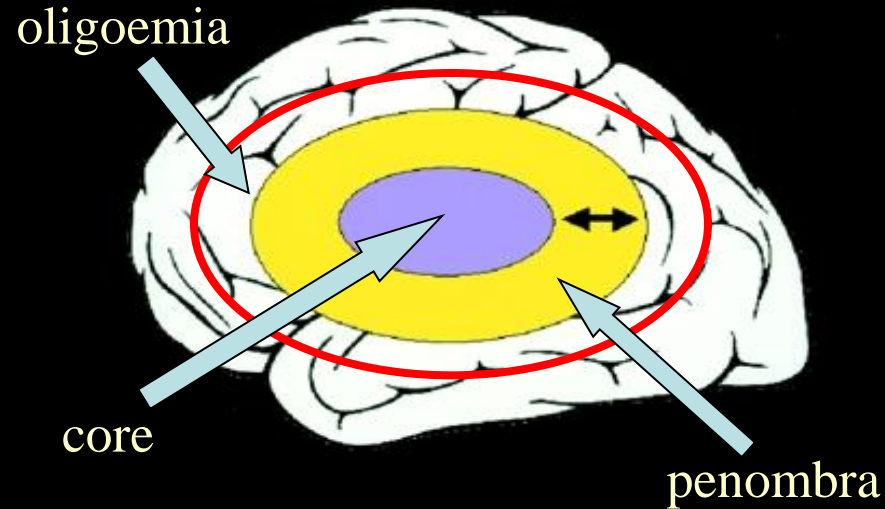
L'ISCHEMIA CEREBRALE



La **ridotta perfusione** è prodotta dall'occlusione di un'arteria cerebrale da parte di un coagulo che si forma in sede (**trombo**) o da un frammento di trombo proveniente da un altro vaso (**embolo**) che causa **l'arresto o la riduzione del flusso ematico cerebrale in corrispondenza del rispettivo territorio di irrorazione**



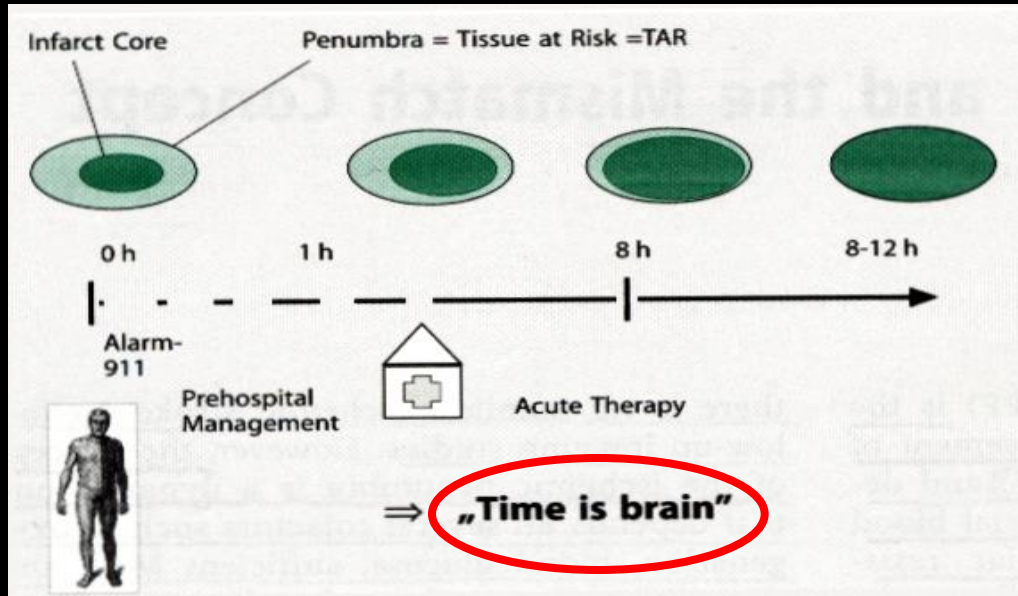
L'AREA ISCHEMICA



Nel contesto di un'**area ischemica** si distinguono **tre zone differenti**:

- 1) una zona centrale, il **core ischemico**
- 2) una zona periferica, la **penombra ischemica**
- 3) una zona perilesionale disposta attorno all'area di penombra, l'**oligoemia benigna**

LA PENOMBRA ISCHEMICA



Se la riperfusione non si realizza, la **penombra ischemica** evolve progressivamente verso l'infarto dopo **circa 8-10 ore** ("time is brain")

penombra



10-20 ml/100gr/min

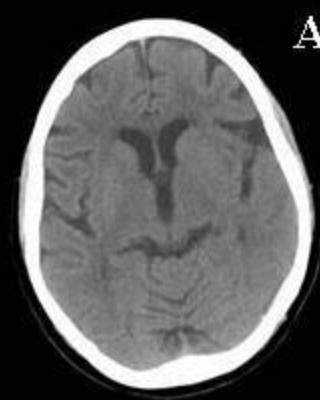


infarto

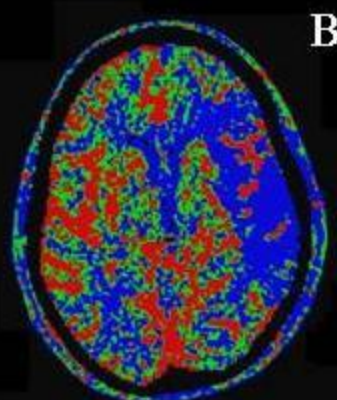
no riperfusione

TERAPIA

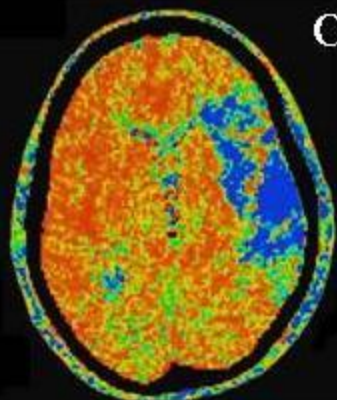
- **Trombolisi sistemica entro 4.5 ore**
- **Trombolisi loco regionale entro 6 ore**
- **Trombolisi meccanica entro 8-9 ore se penombra**



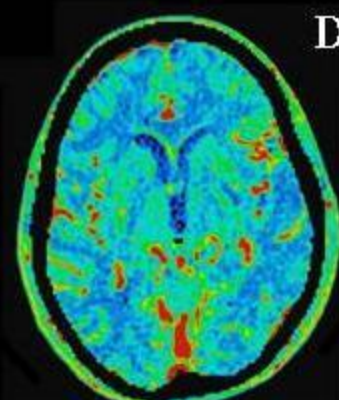
A



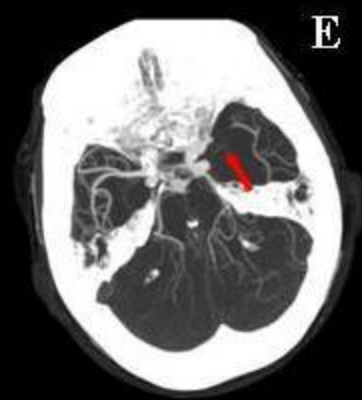
B



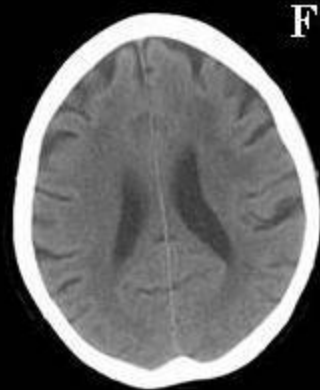
C



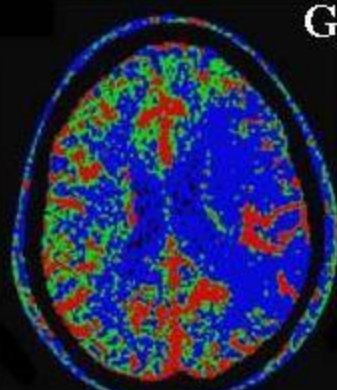
D



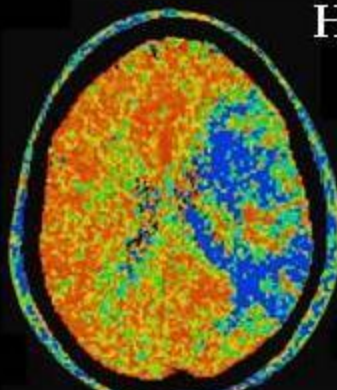
E



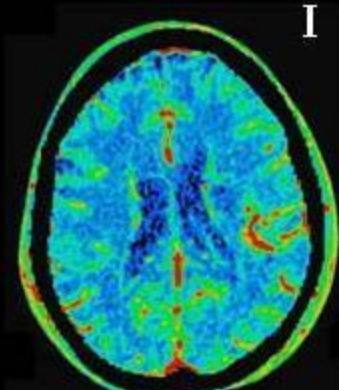
F



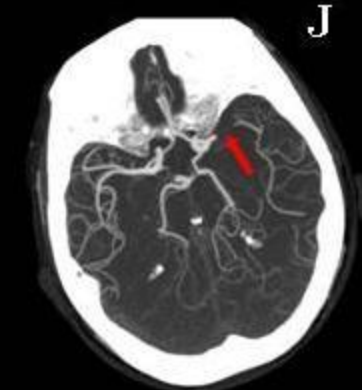
G



H



I



J

CT

CTP- CBF

CTP-MTT

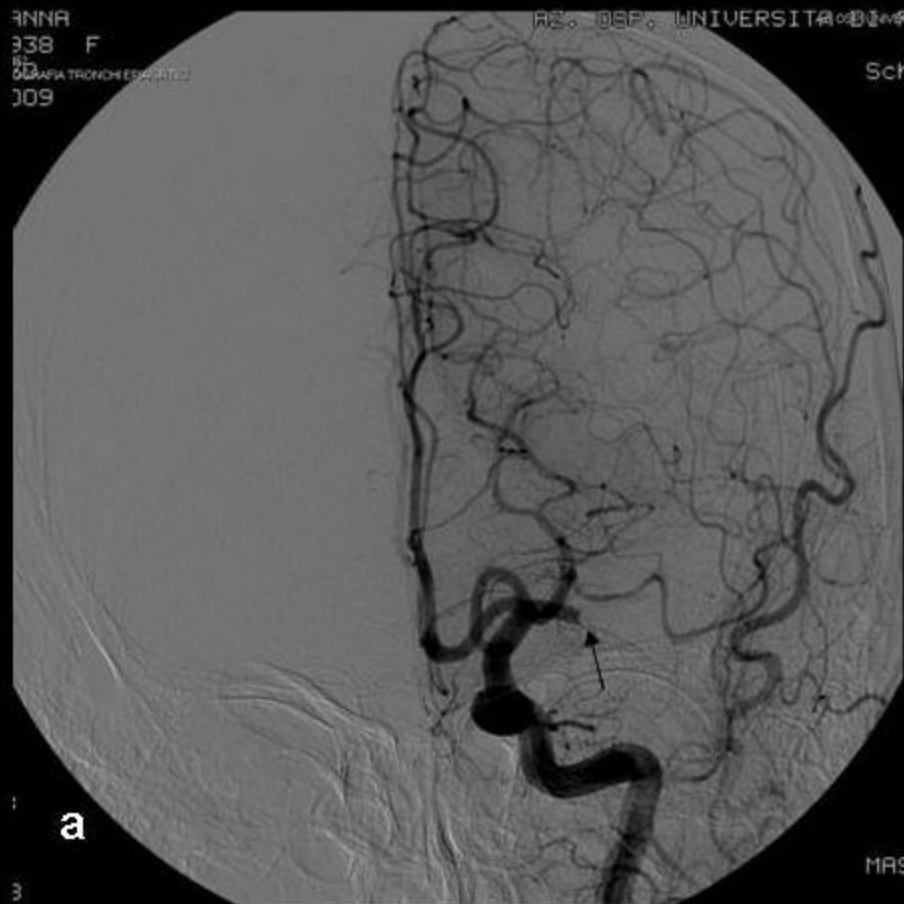CTP-CBV

CTA

ANNA
338 F
02/02/2014
02/02/2014
009

RS. OSP. UNIVERSITA'

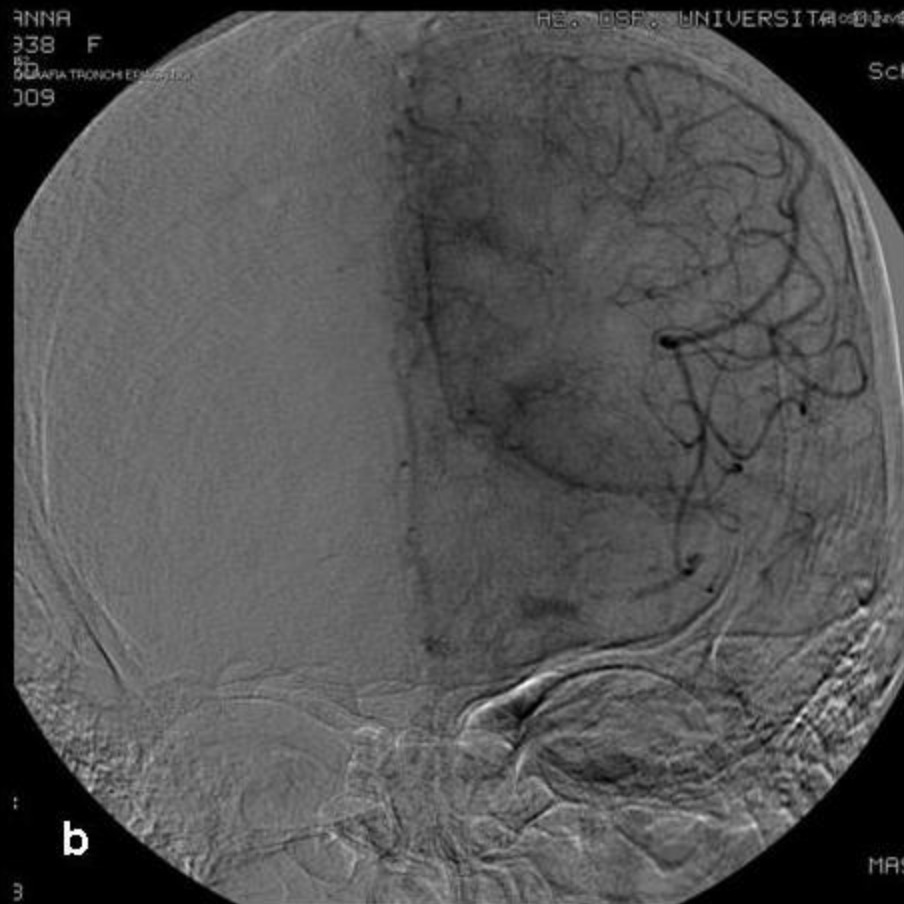Sch

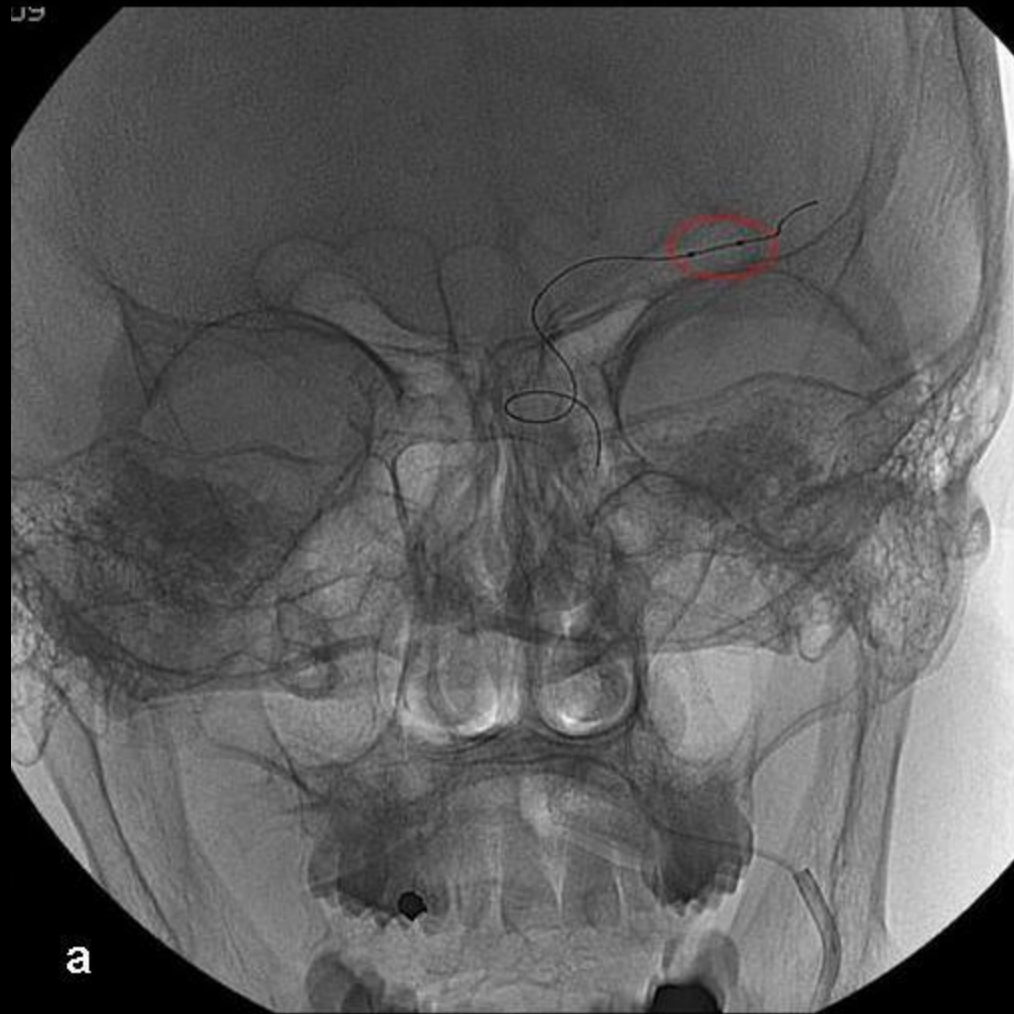


ANNA
338 F
02/02/2014
02/02/2014
009

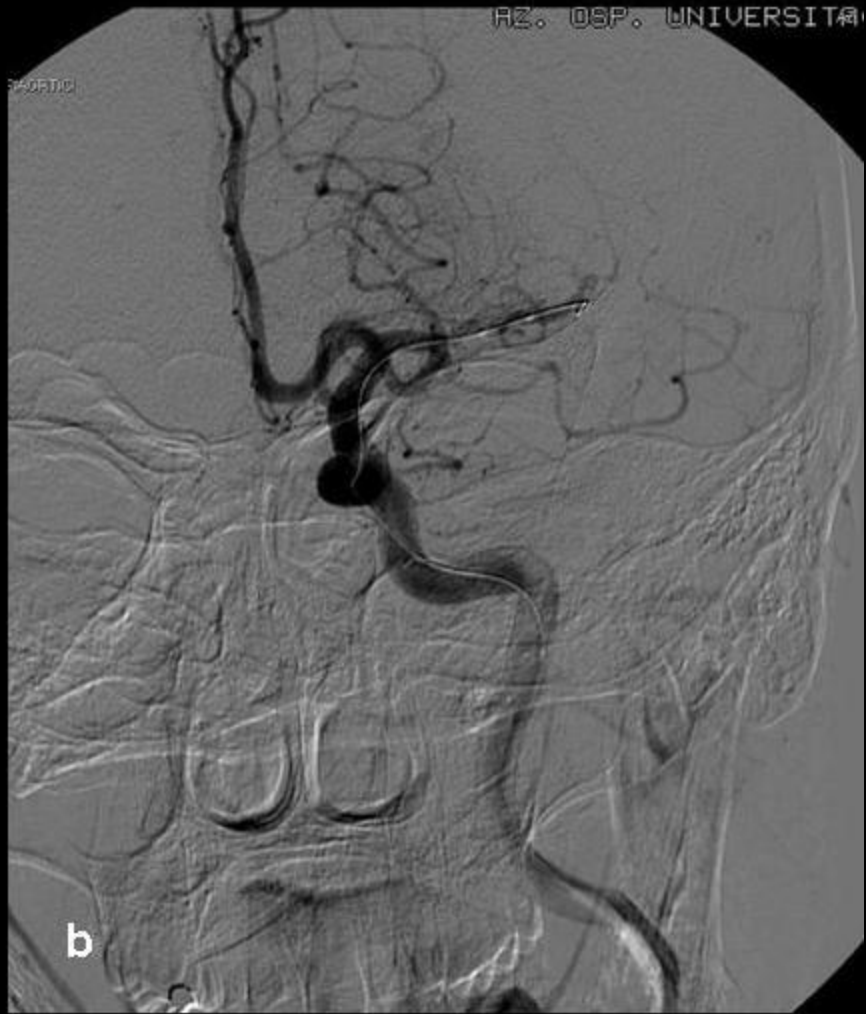RS. OSP. UNIVERSITA'

Sch

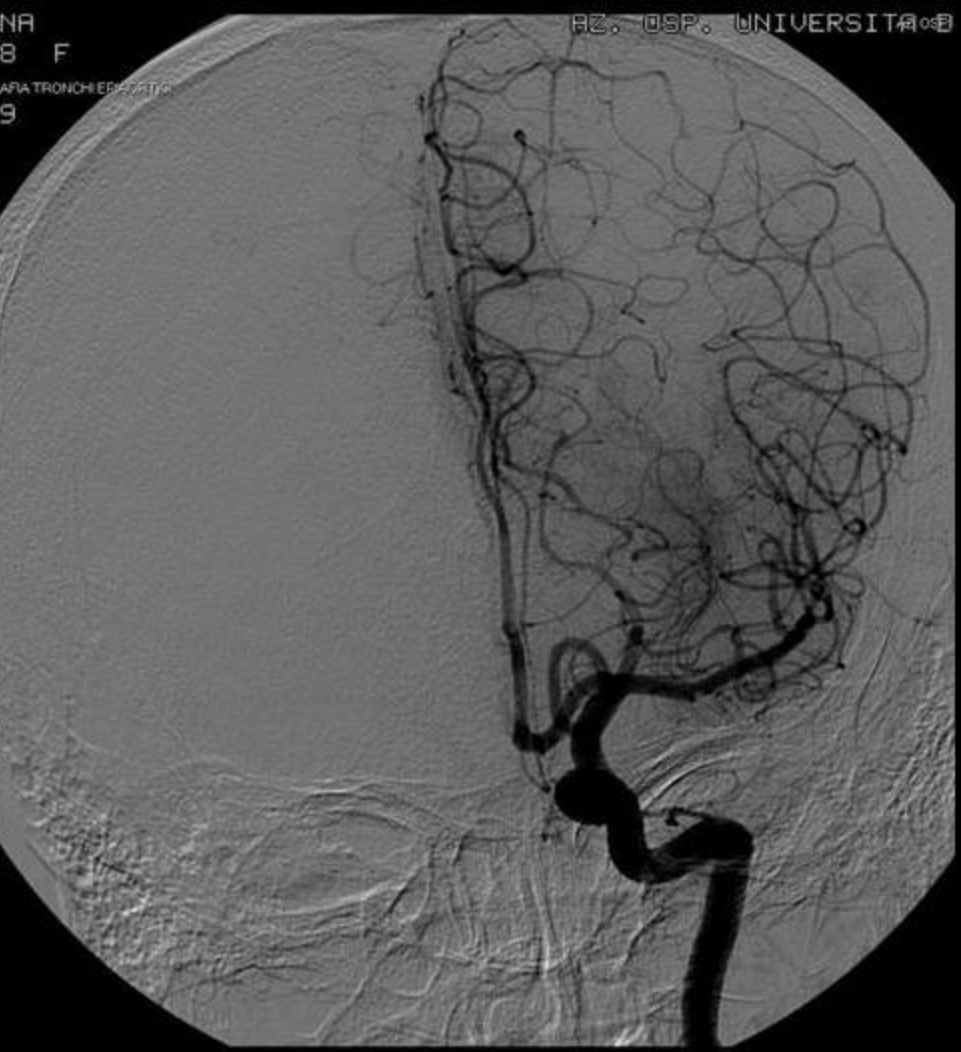
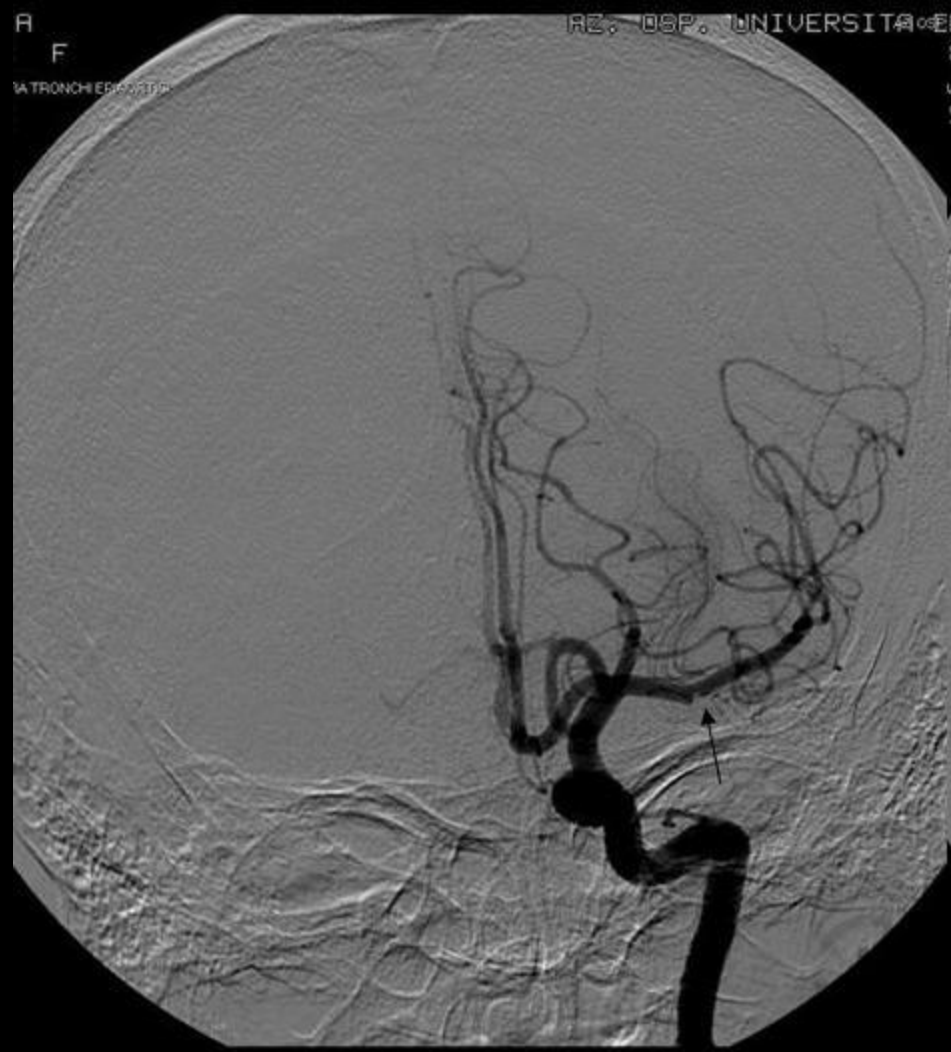
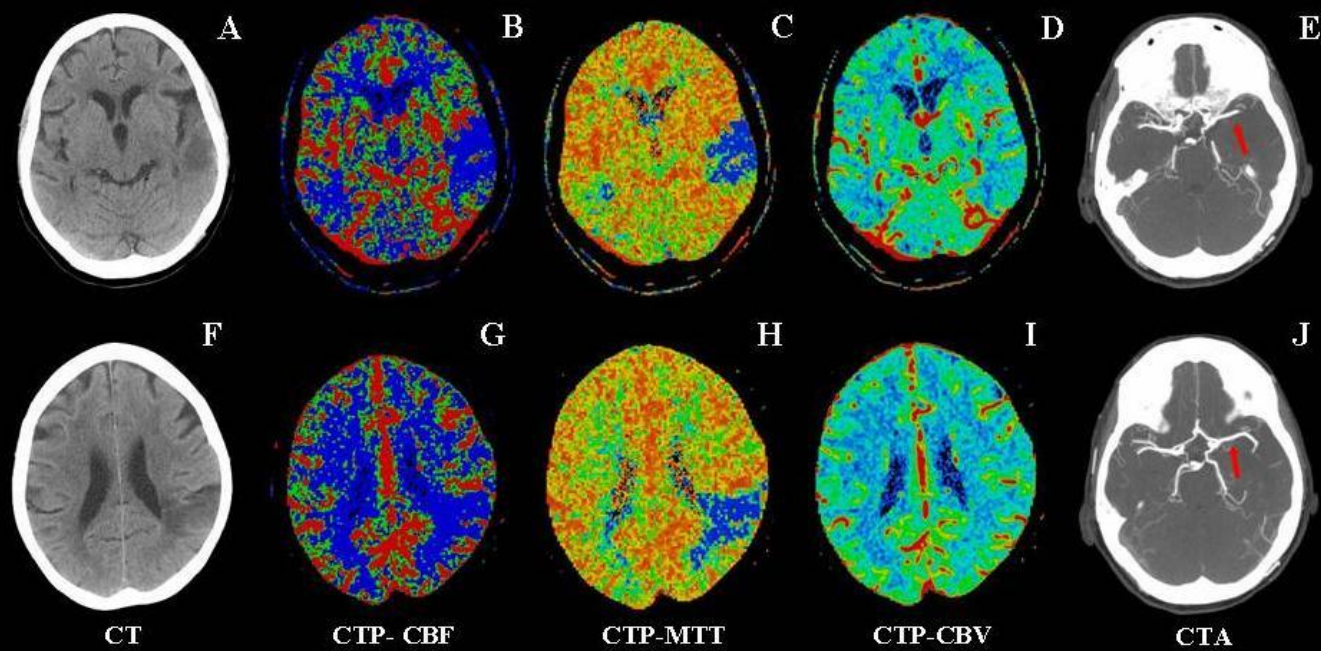
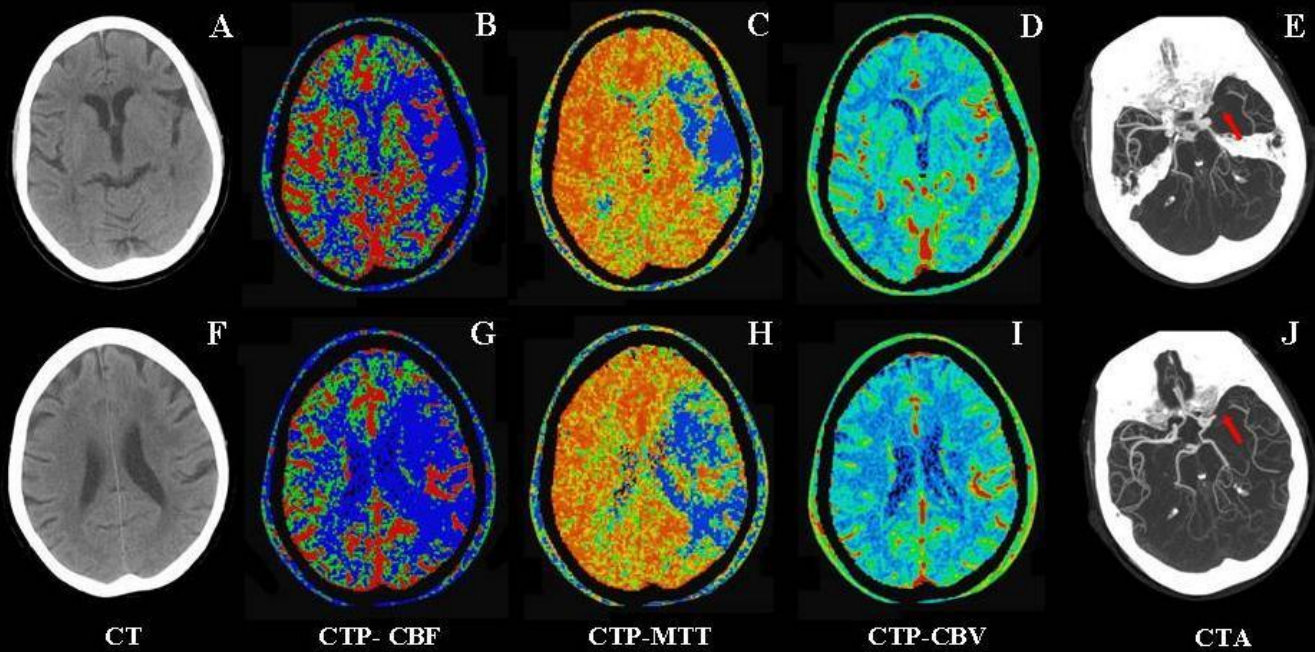


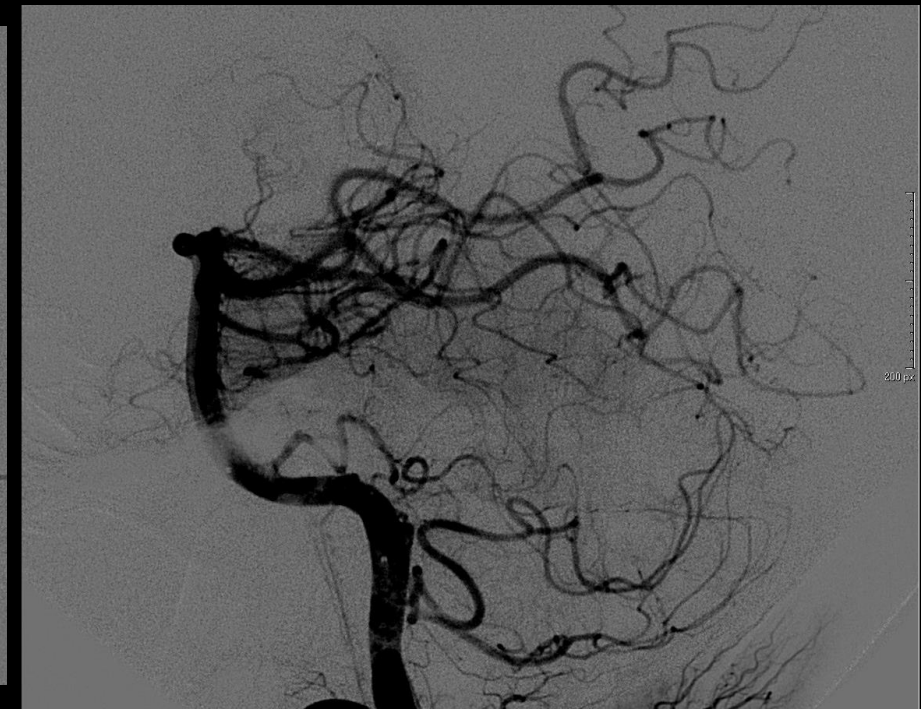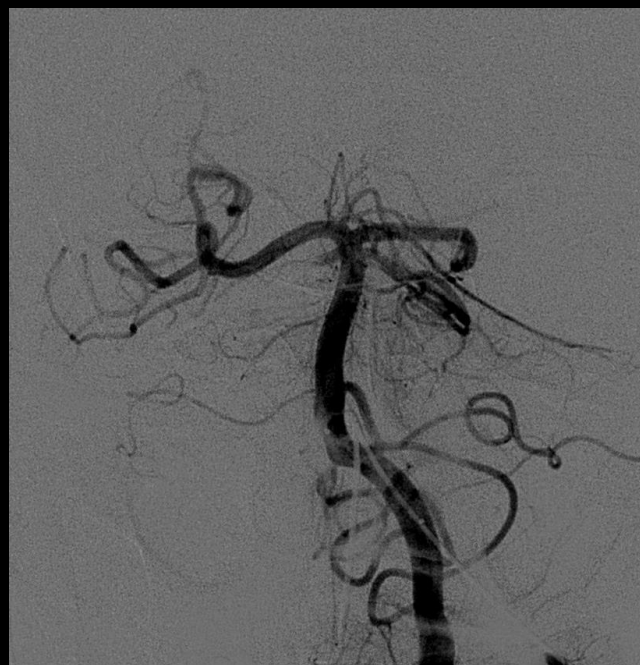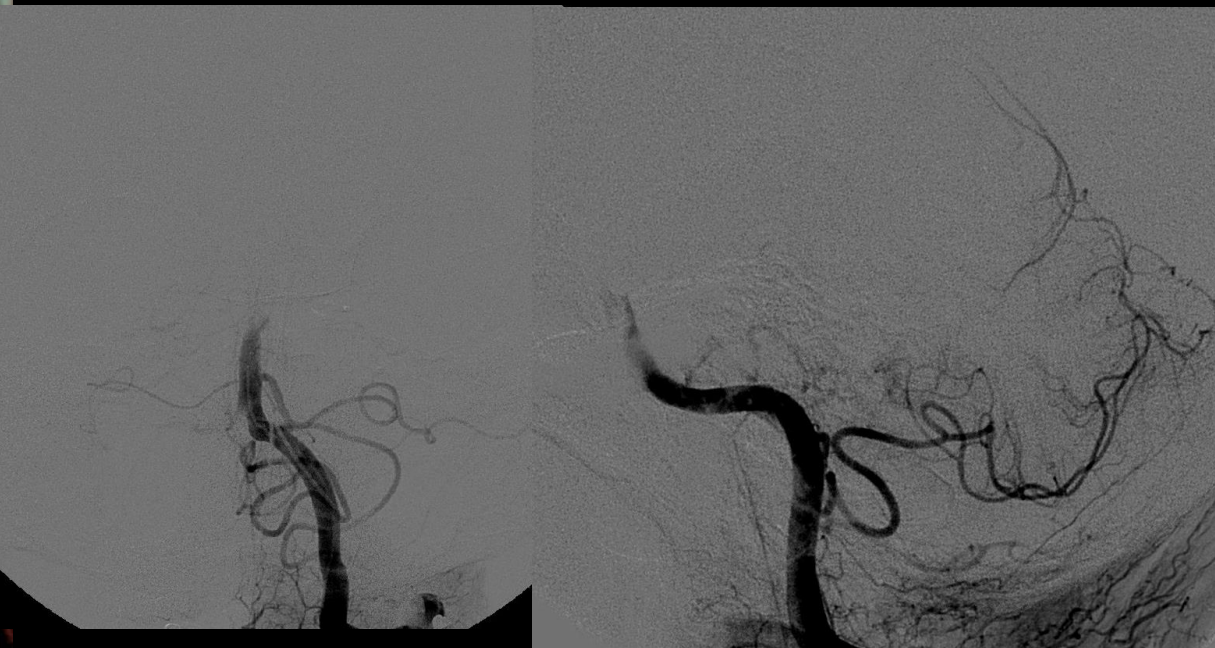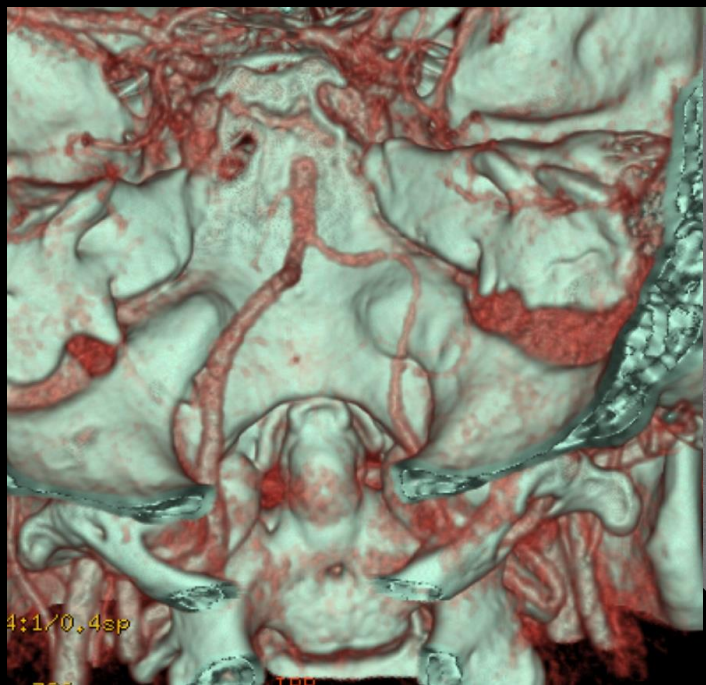
a



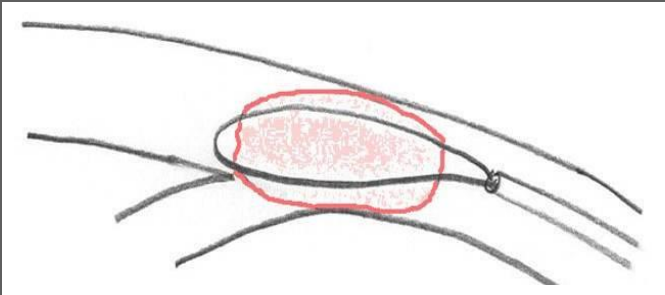
b





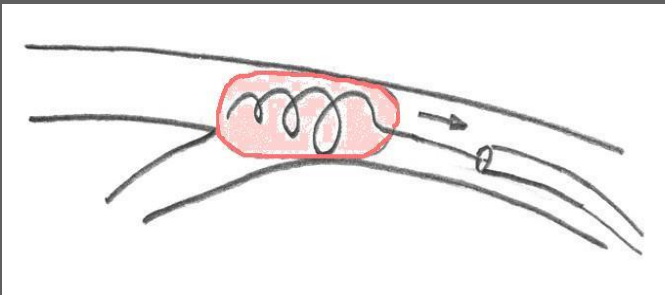


Sistemi disponibili



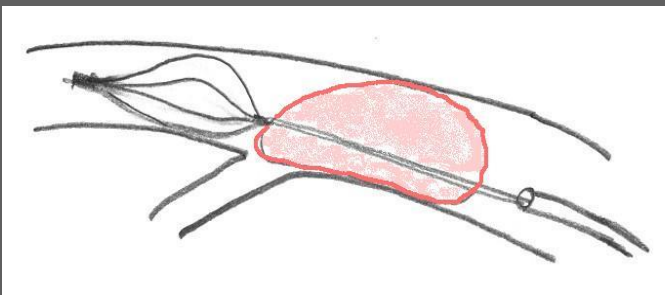
LASSOO (BALT Extrusion, Boston Sc., ...)

- Inizialmente disegnato per recupero delle spirali



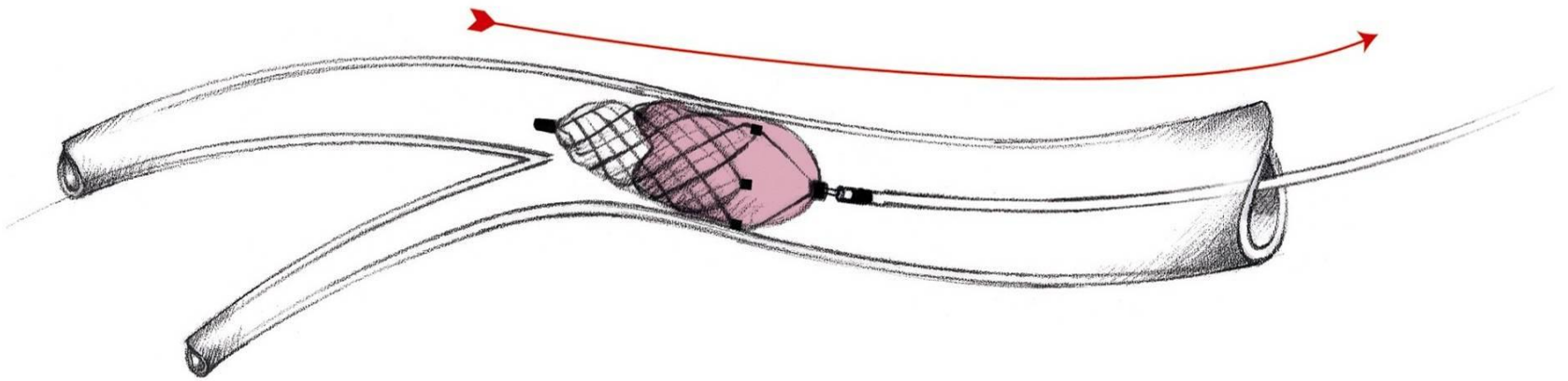
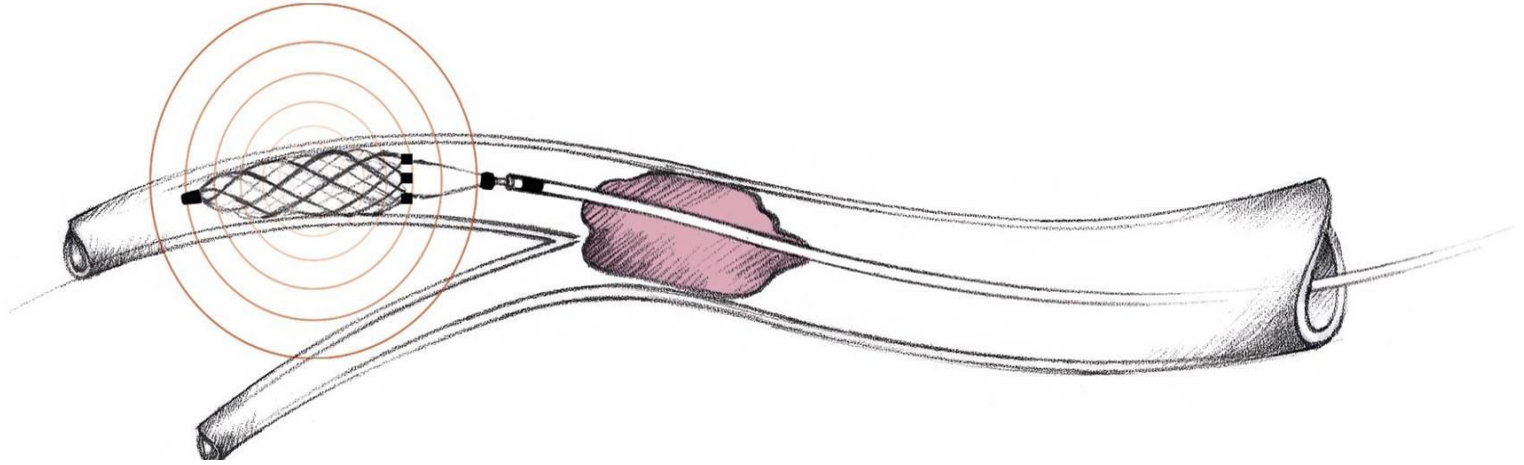
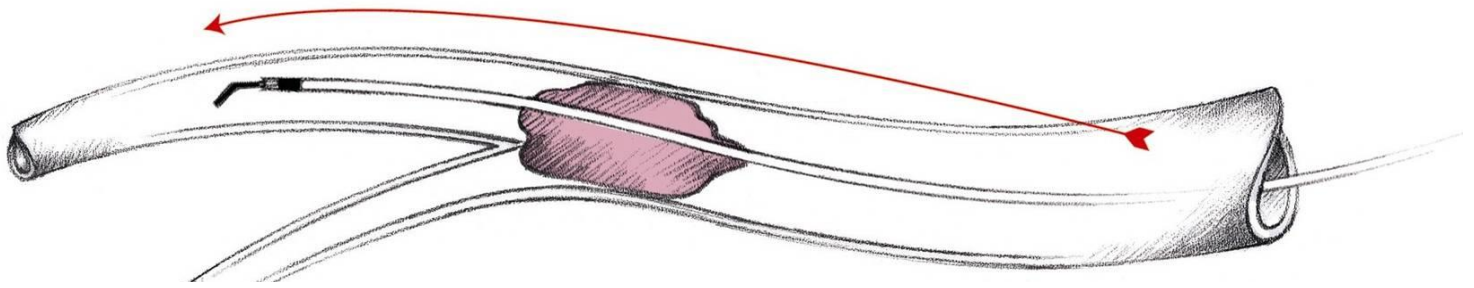
MERCI™ (Concentric Medical)

- « Cavatappi »
- 50% successo

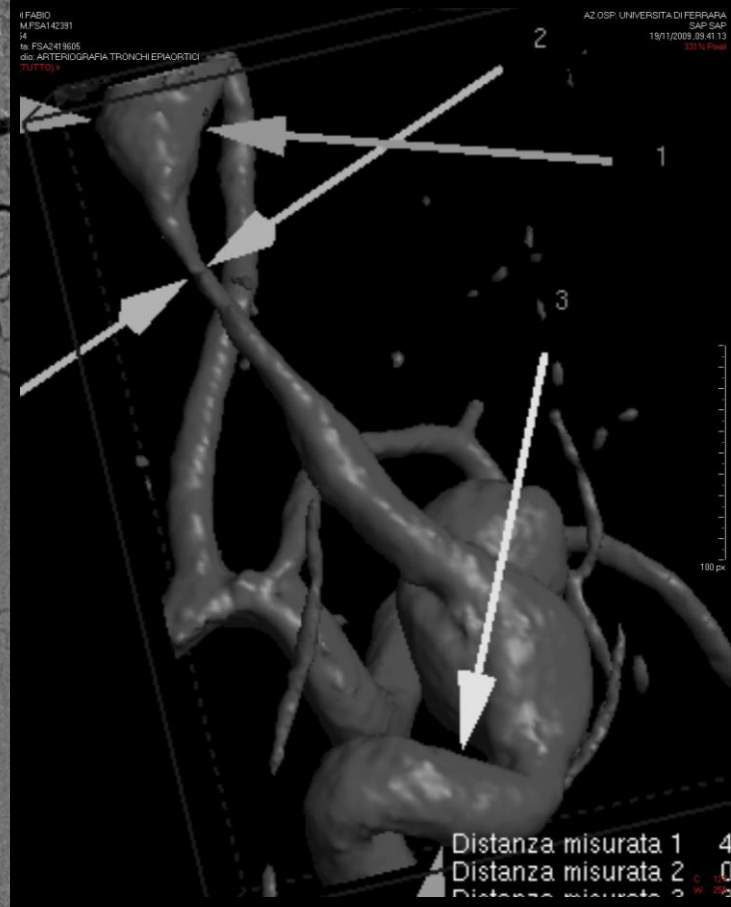
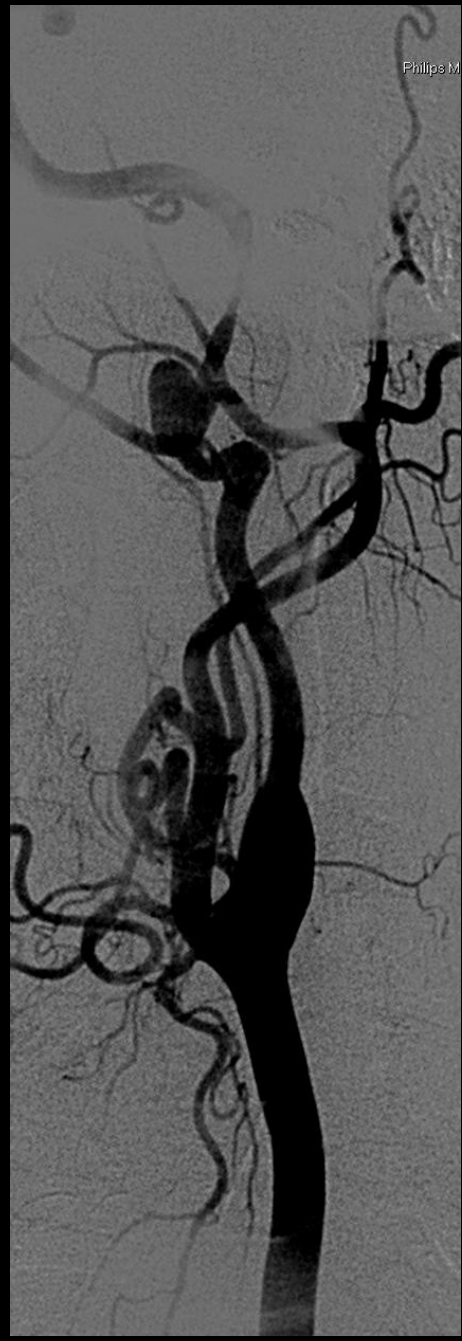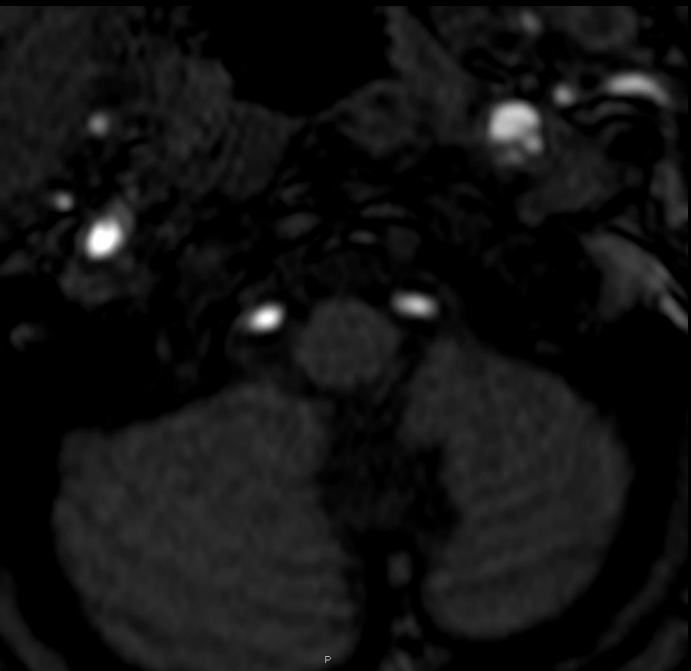
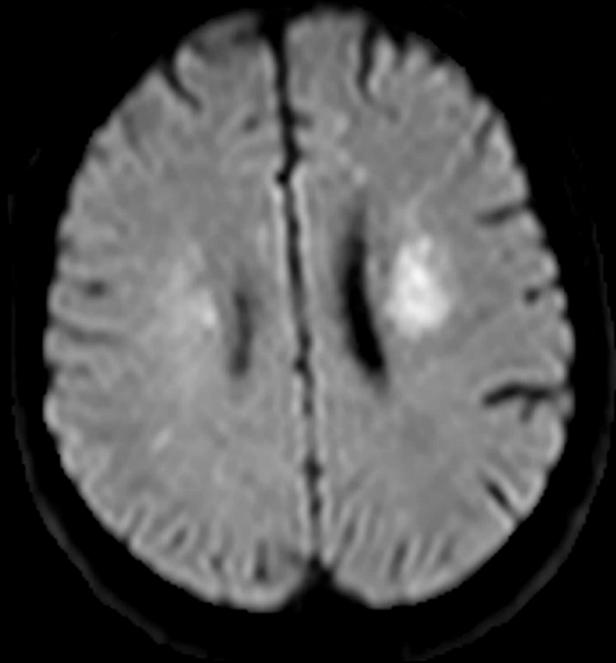


IN-TIME™ (Boston Scientific)

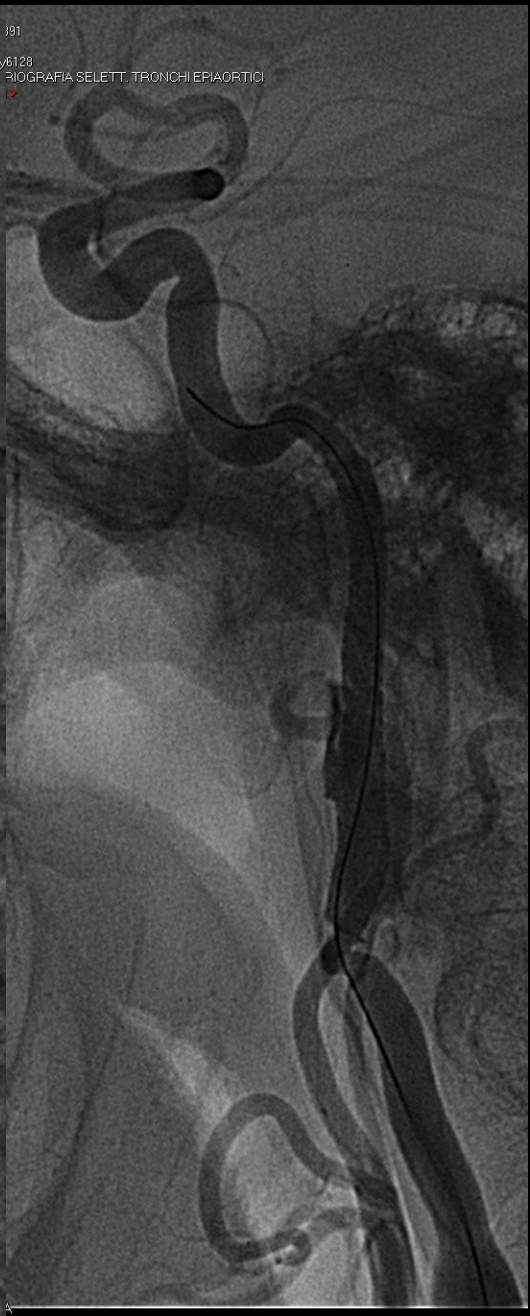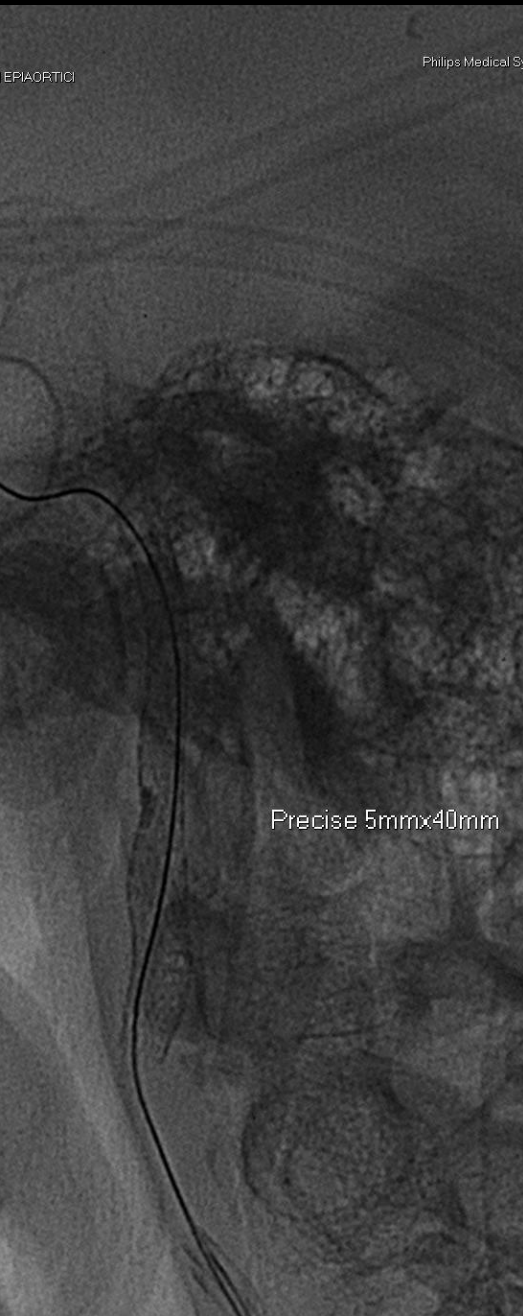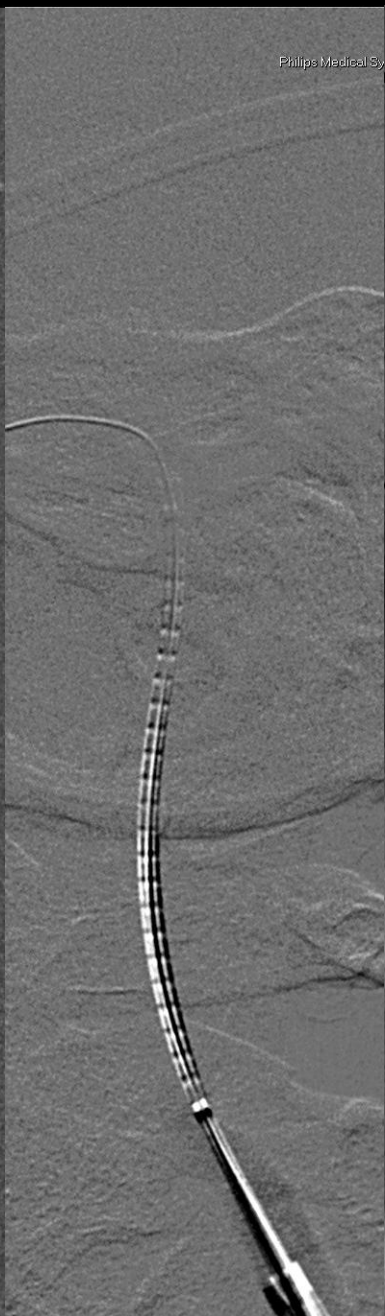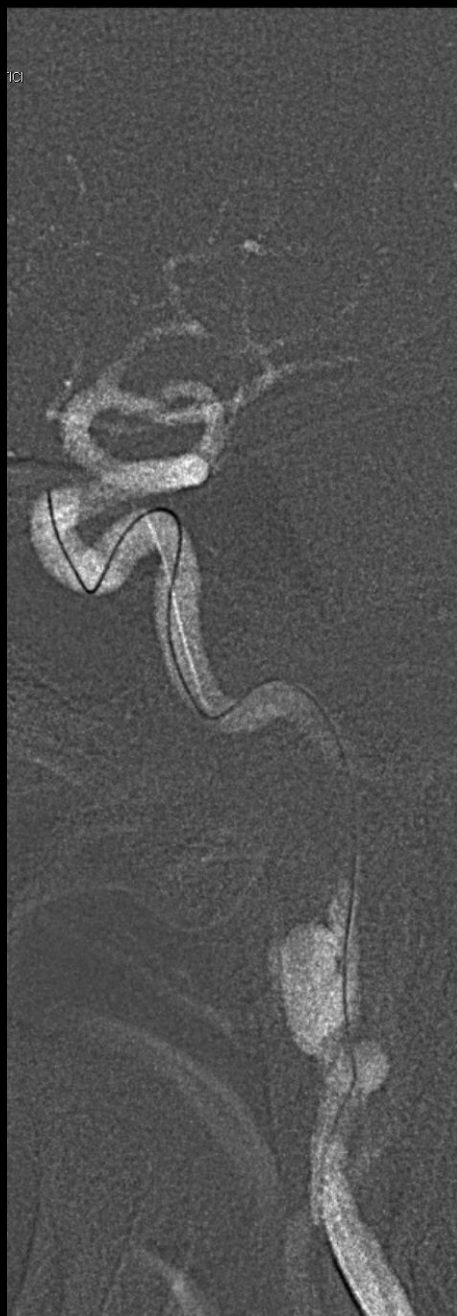- Dormia system
- Troppo rigido per uso intracranico

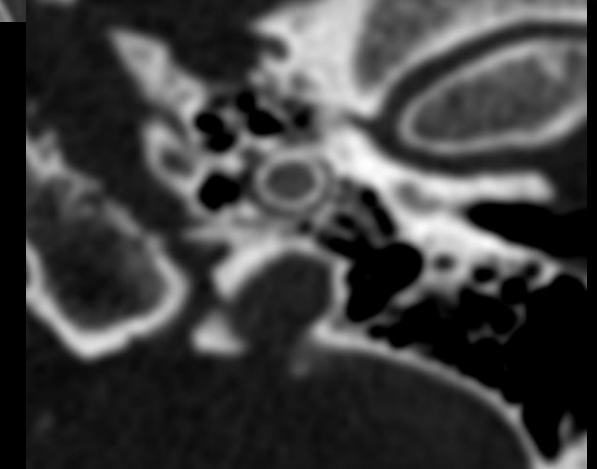
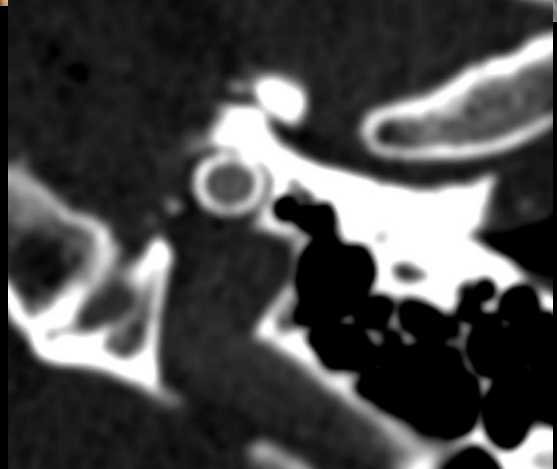
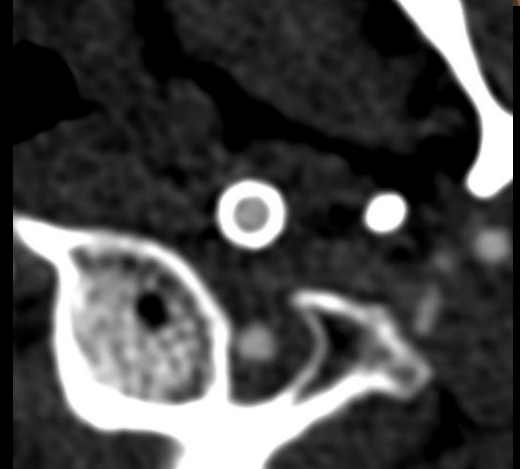
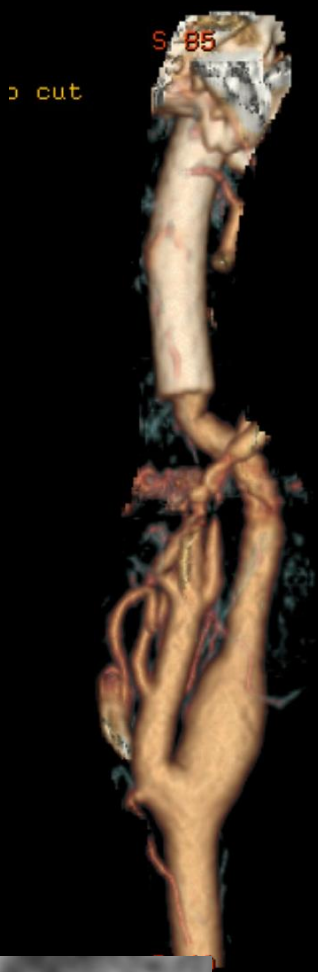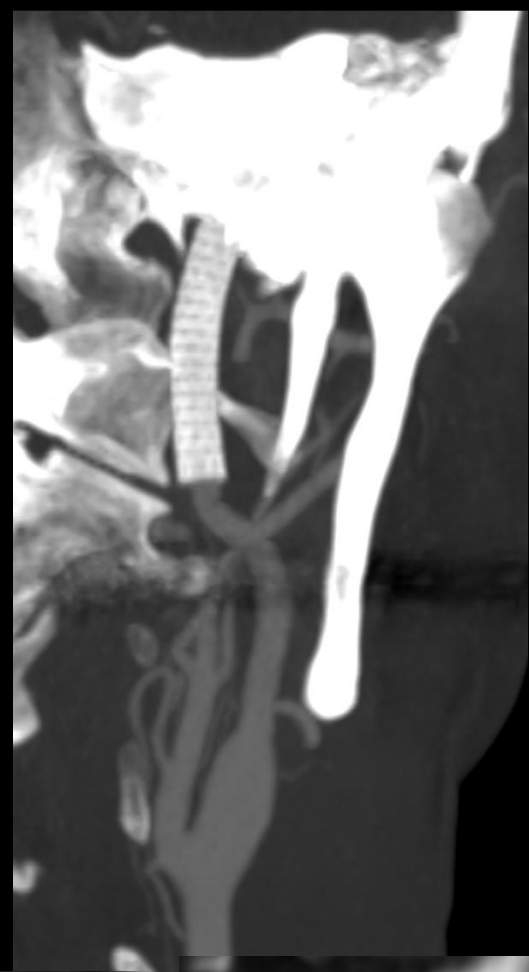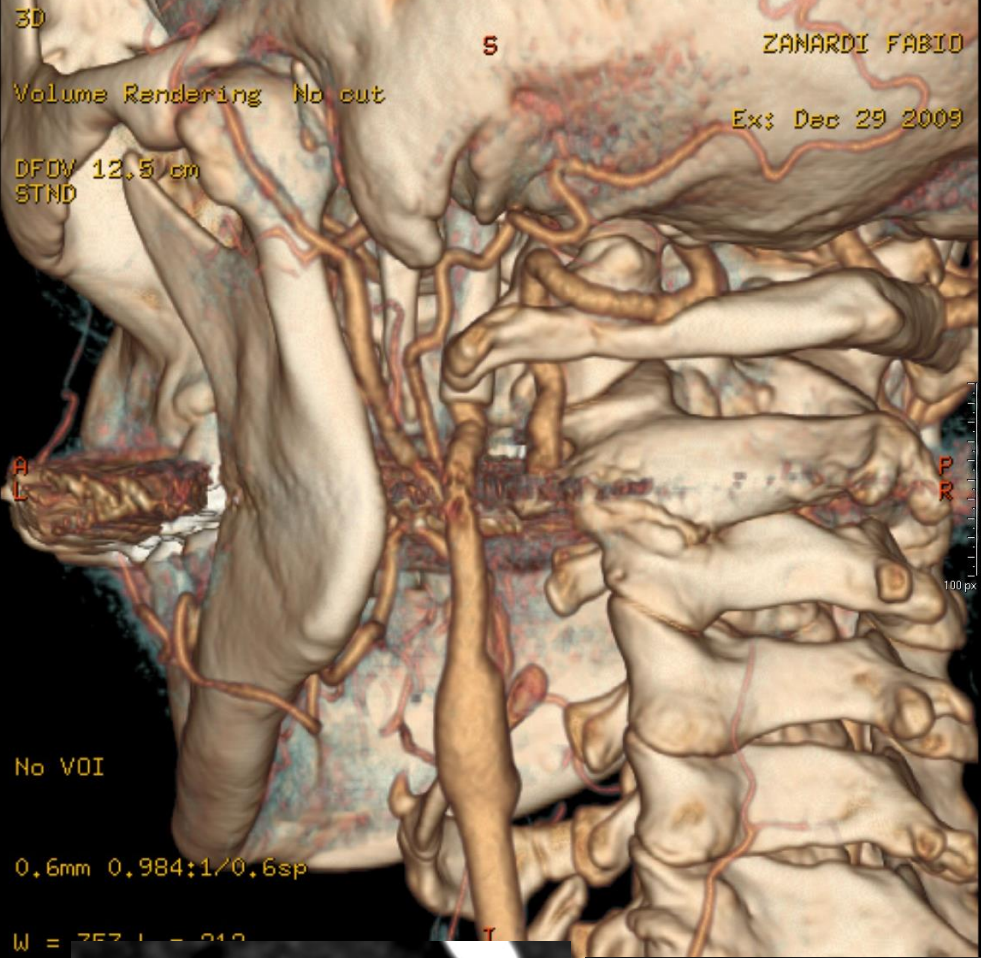


STENTING CAROTIDEO



Dissezioni

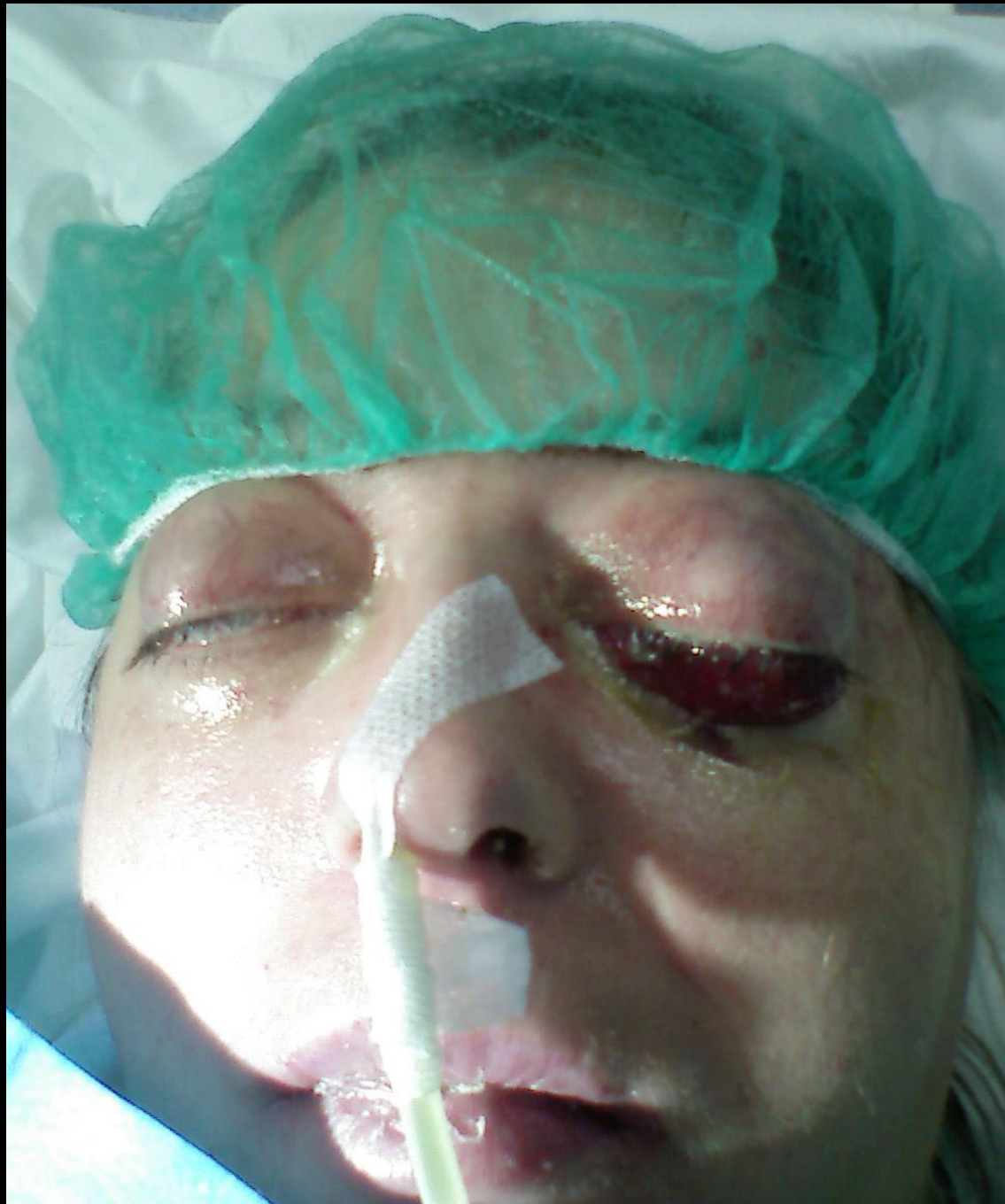

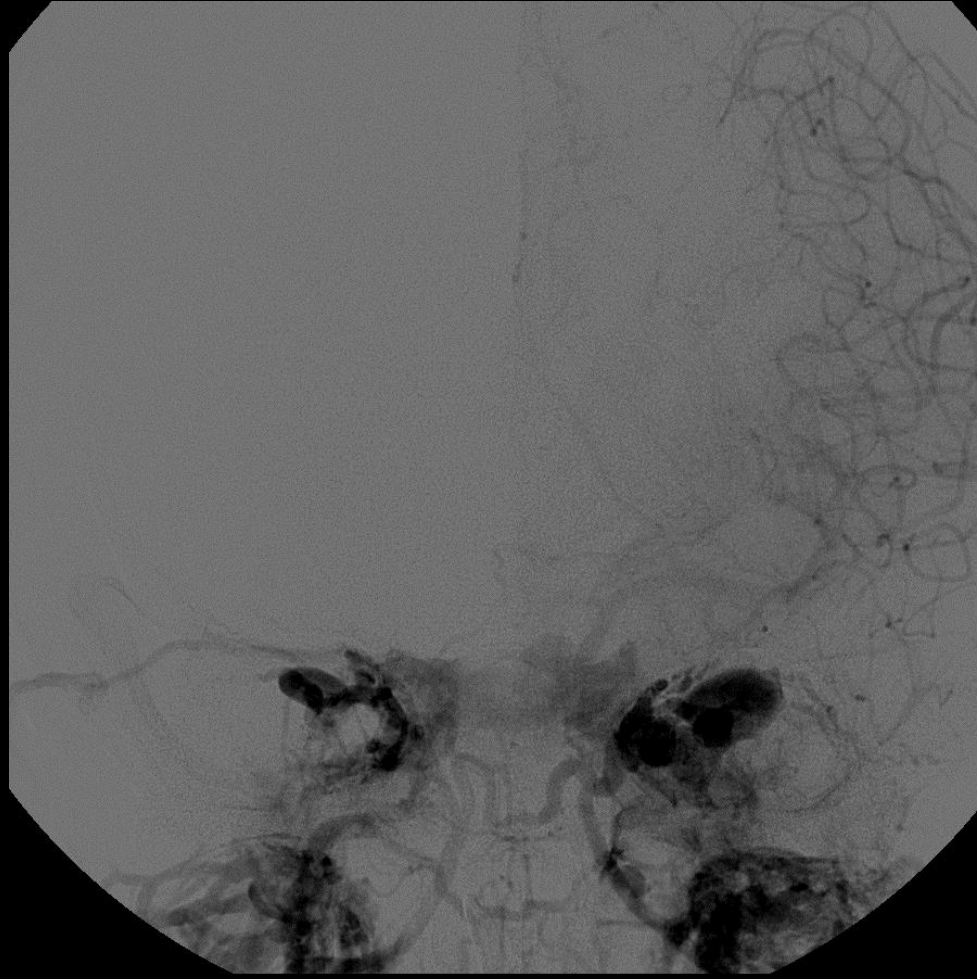

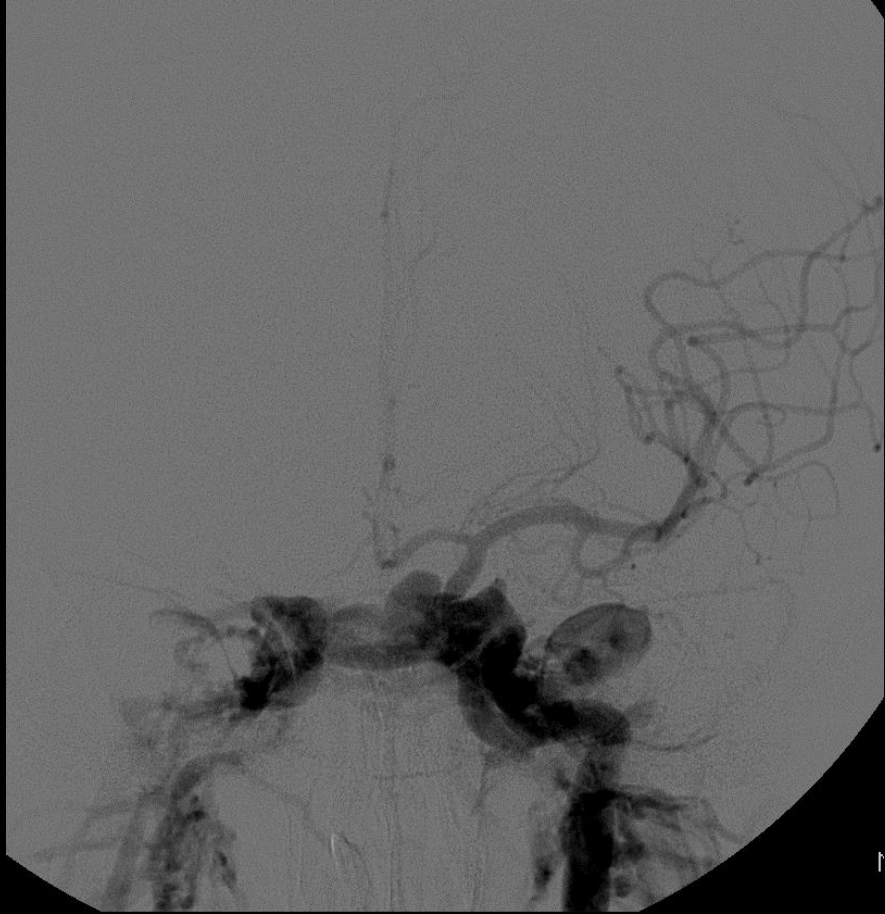


Stenosi carotidea

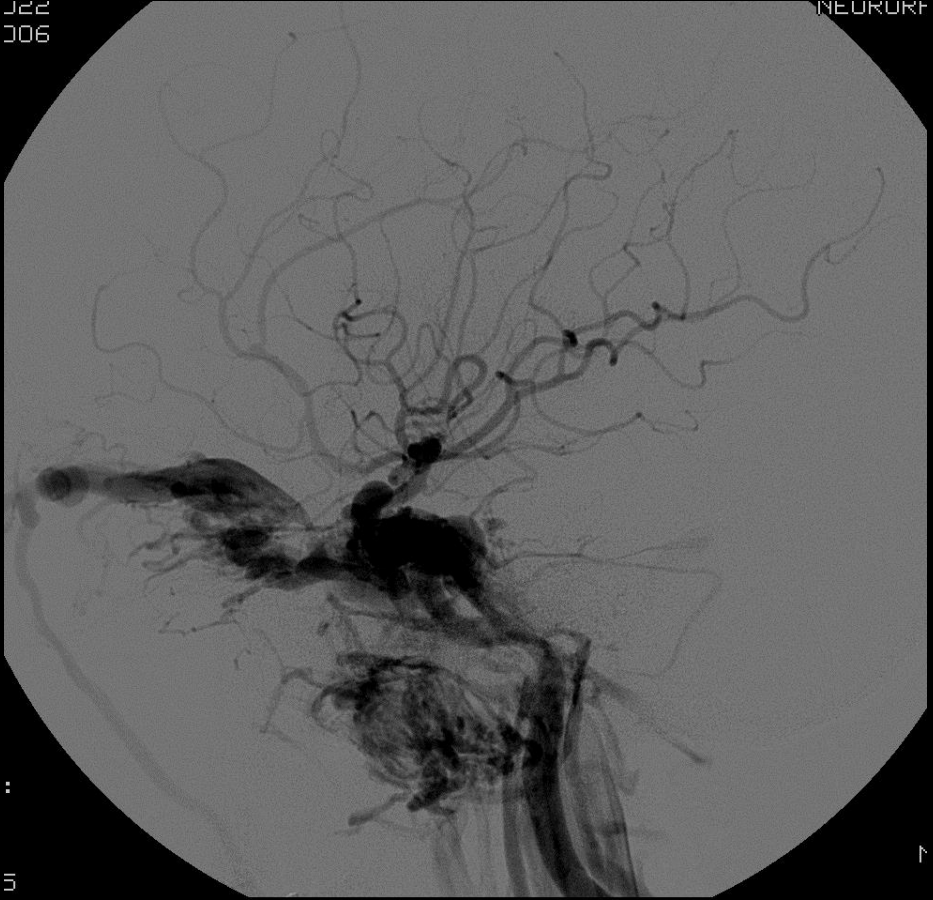
FISTOLA CAROTIDO CAVERNOSA





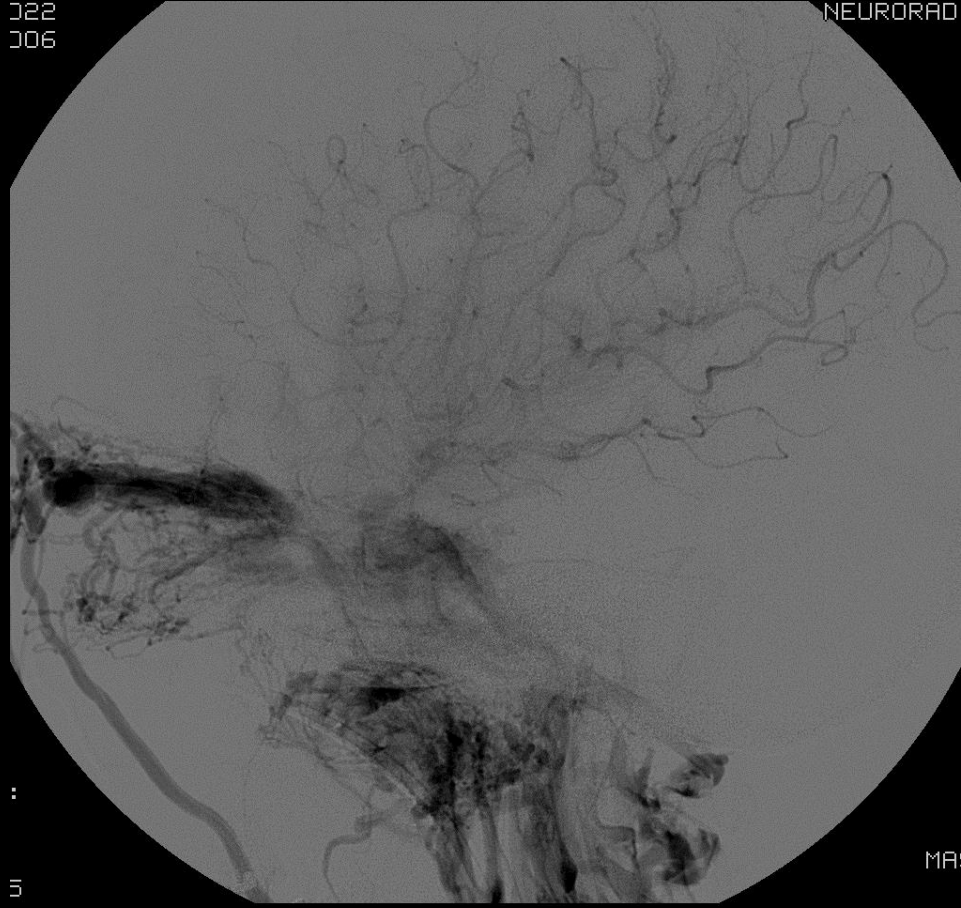
J22
J06

NEURORAD J22
J06



5

NEURORAD



5

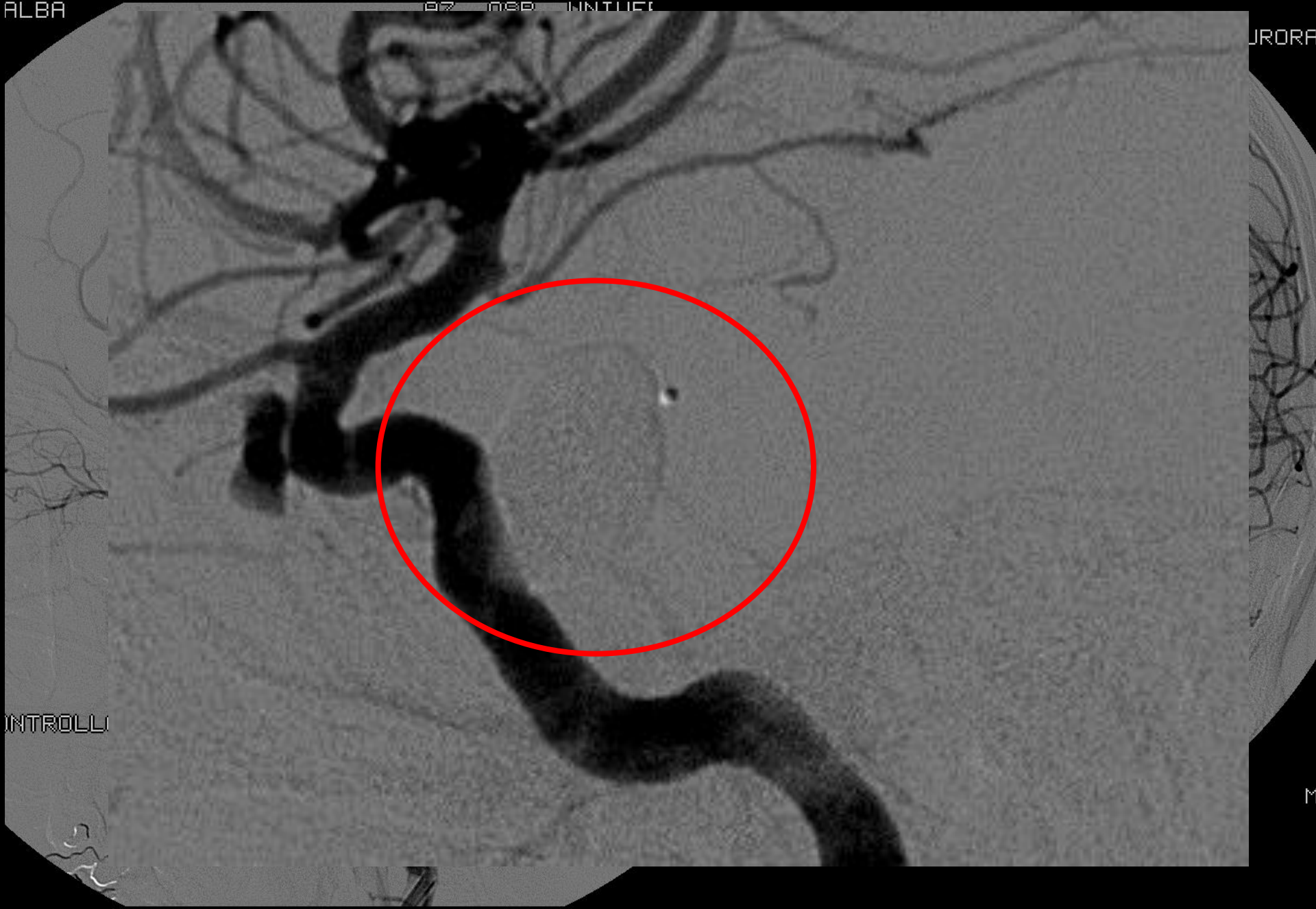MR

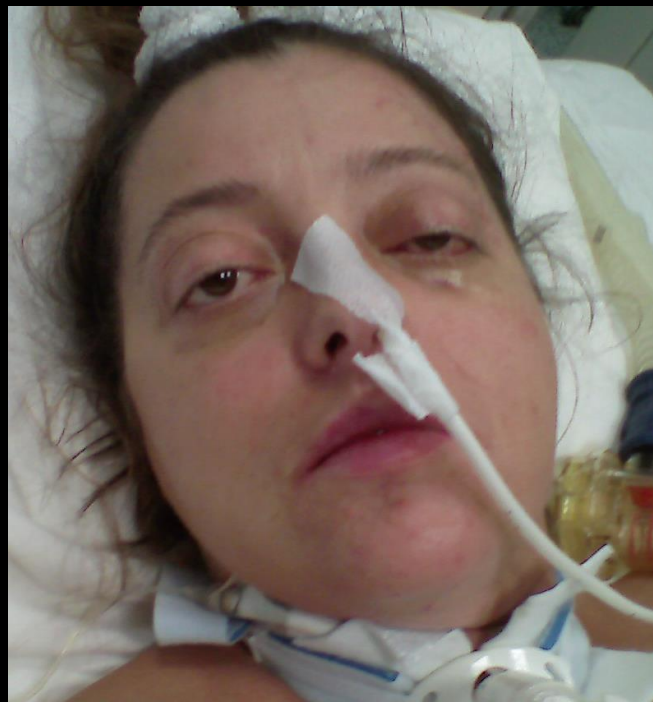
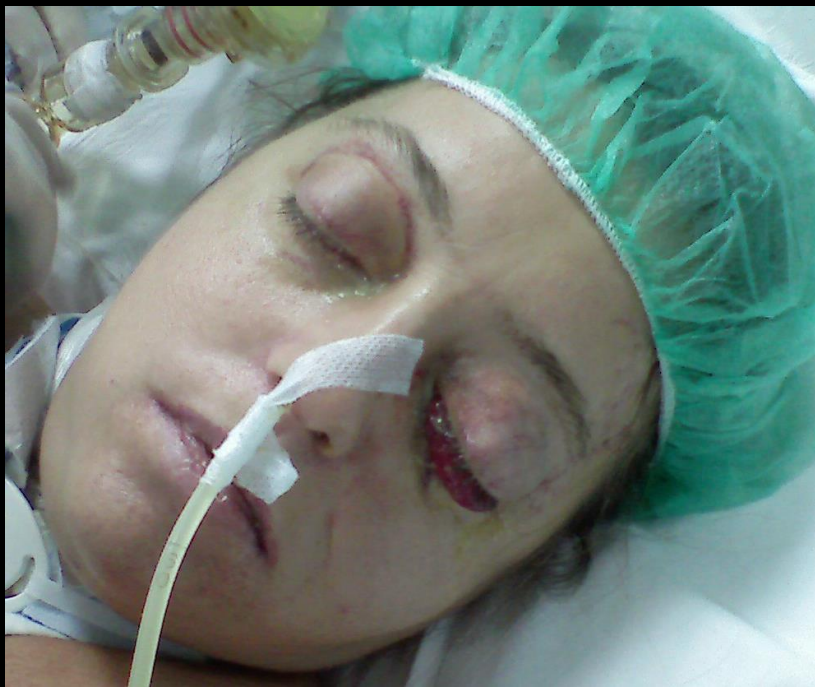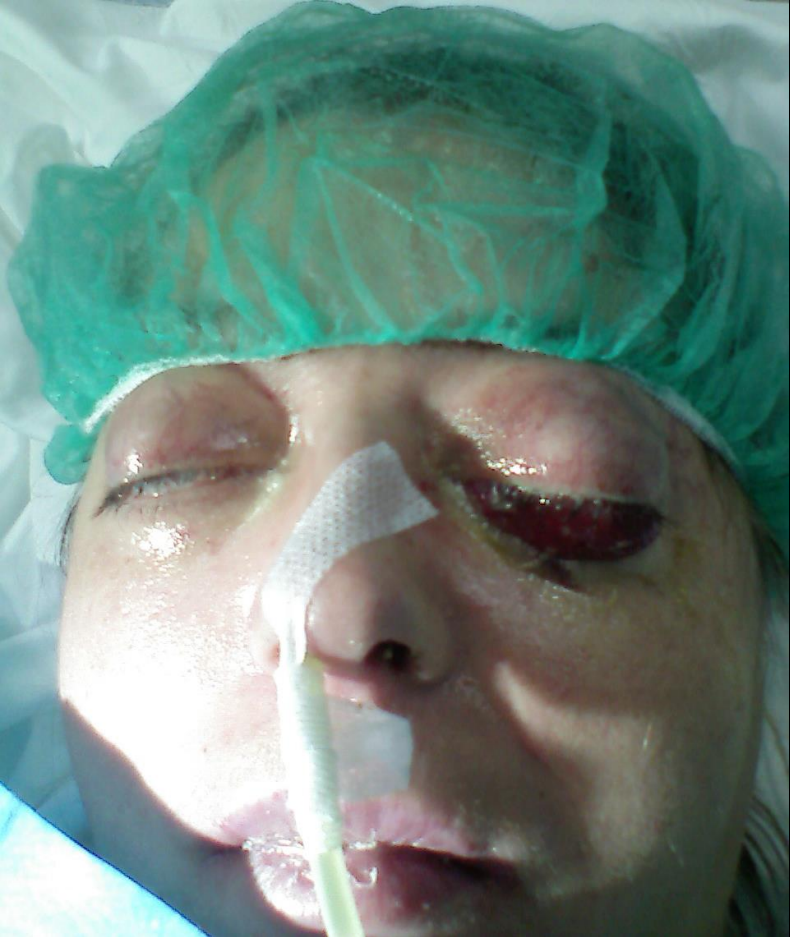ALBA

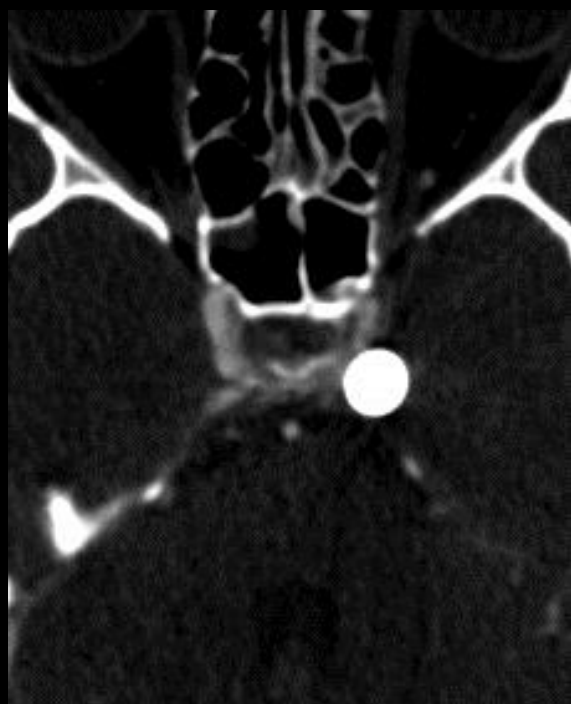
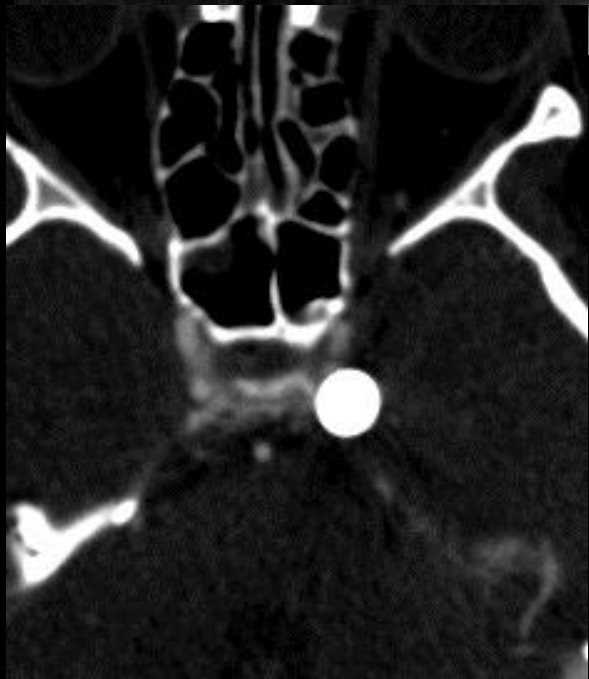
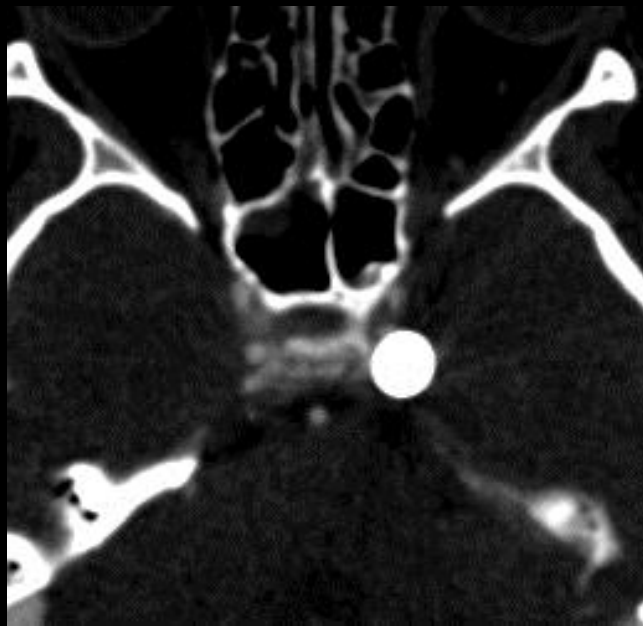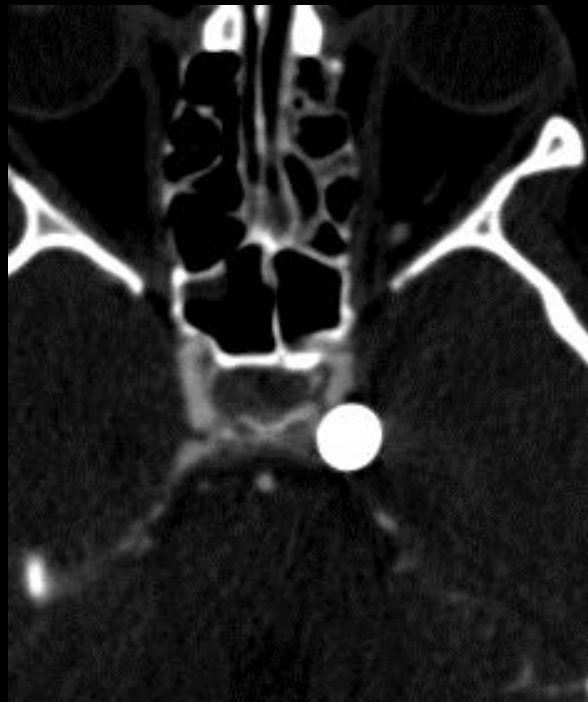
07 080 INTUFI

URORA

CONTROLLI







FISTOLA DURALE

C.M Maschio 61 aa

16/5/06 P.S: Trauma cranico senza perdita di coscienza

GCS 14. Cefalea

TC cerebrale urgente: frattura occipitale paramediana sn
ematoma contusivo intraparenchimale

Dimissione

19/6/06 P.S: Riferita disartria e stato confusionale

Non deficit neurologici focali

TC cerebrale urgente: falda ipodensa frontale dx

RM cerebrale: trombosi seni venosi

Dimissione

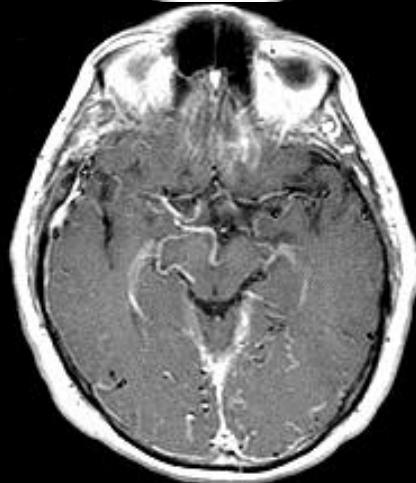
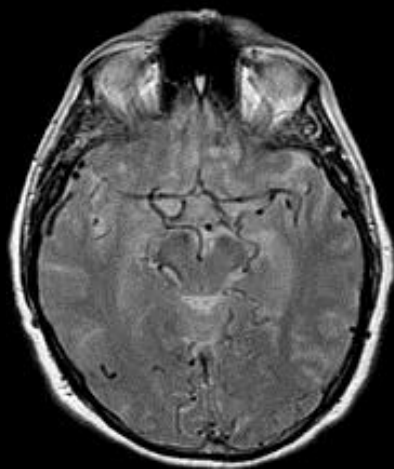
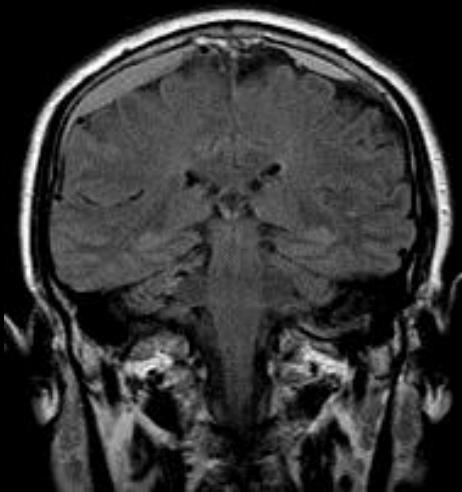
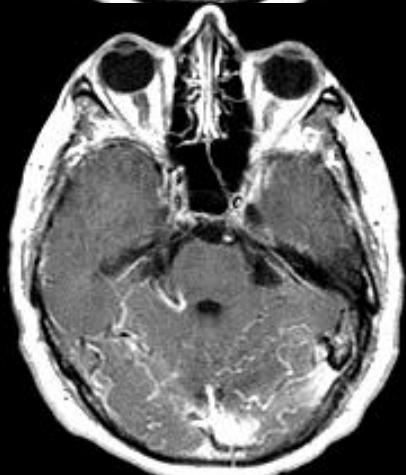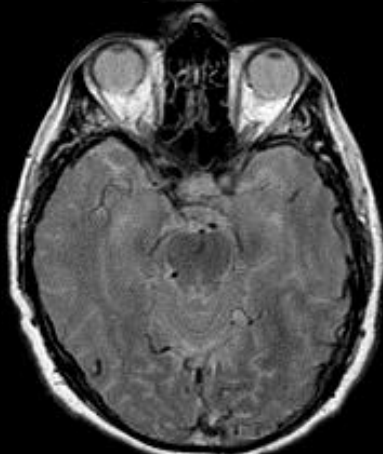
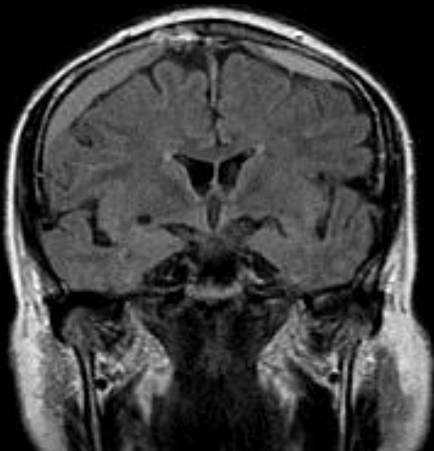
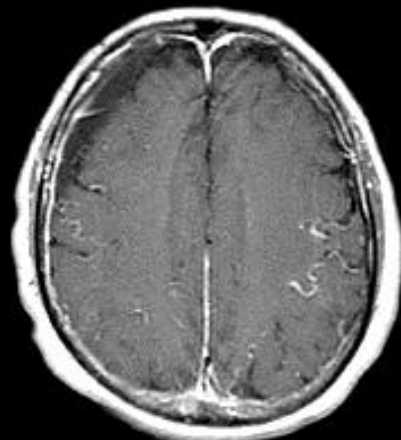
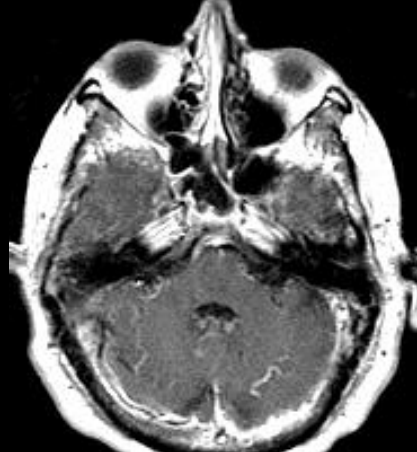
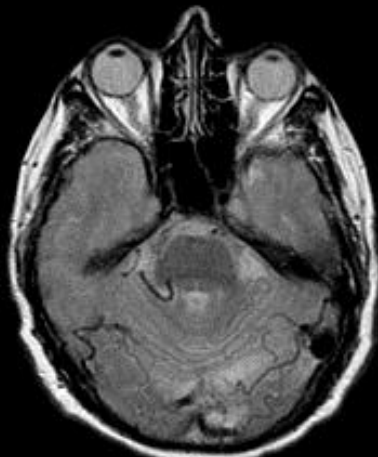
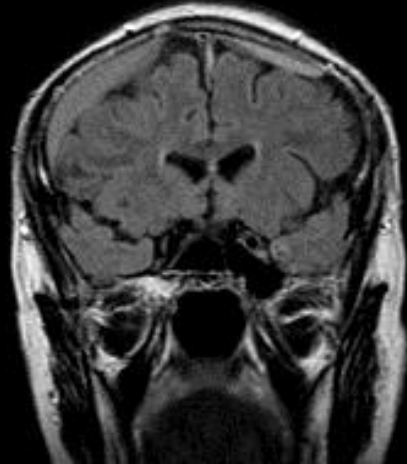
9/10/06 P.S: Stato di coma

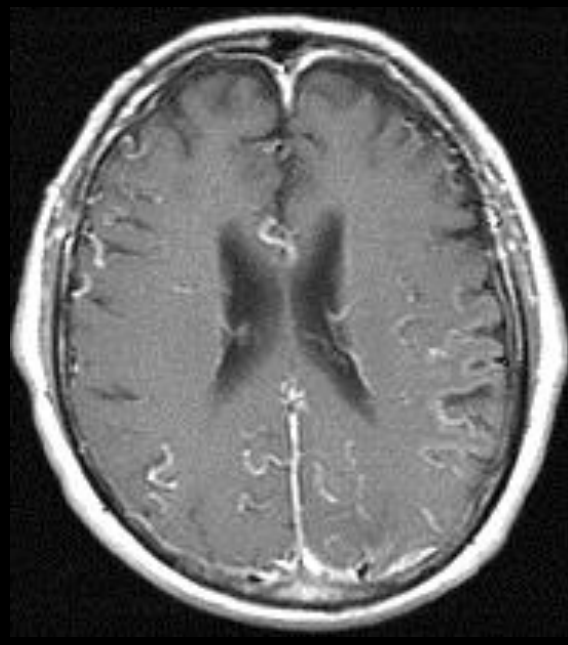
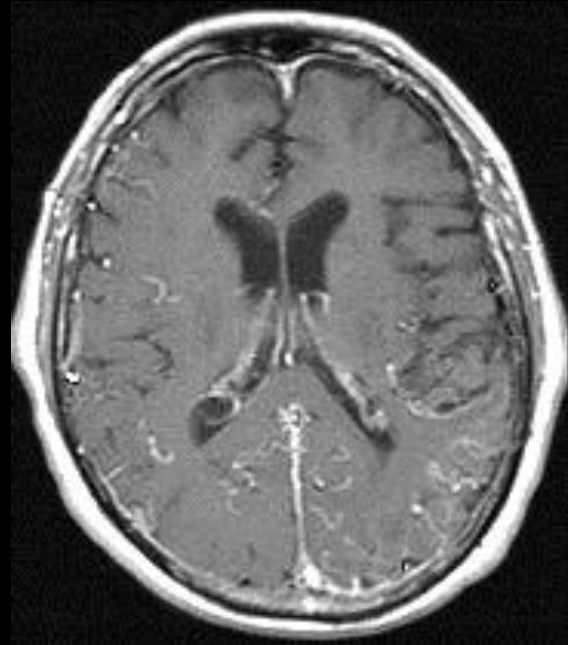
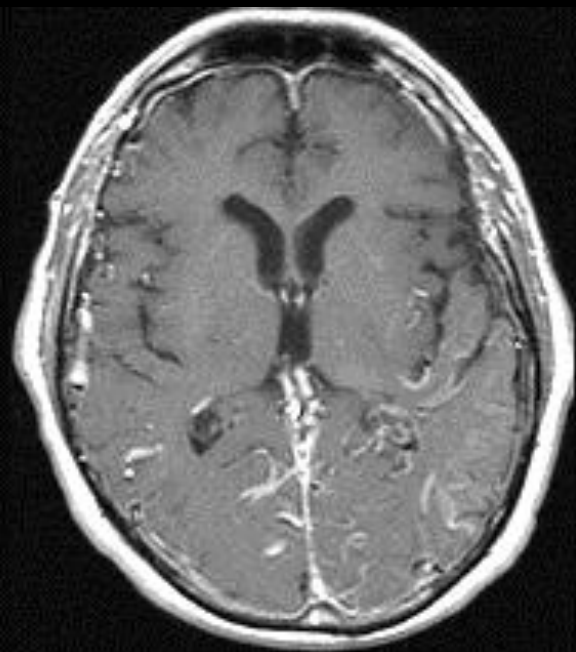
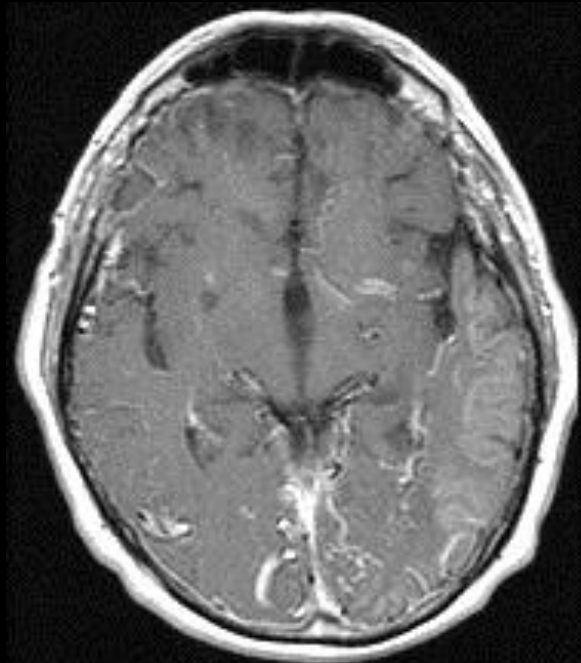
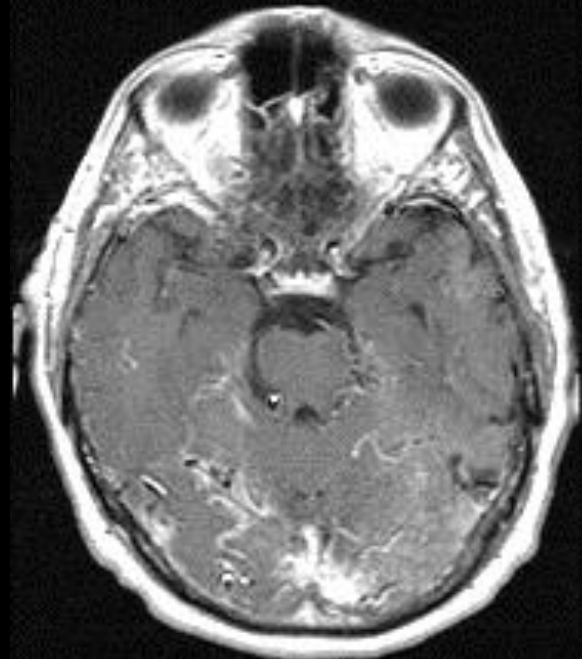
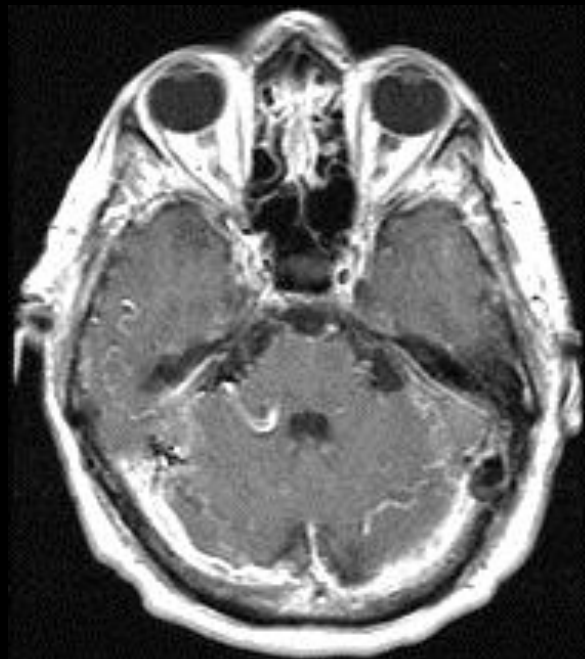
TC cerebrale urgente: falda ipodensa con segni di
Sanguinamento più recente. Dimissione

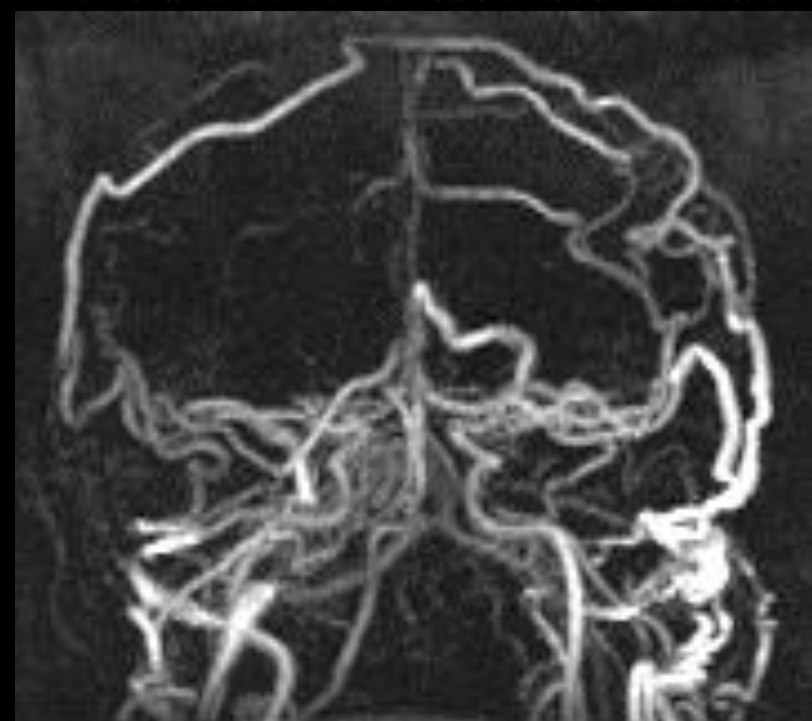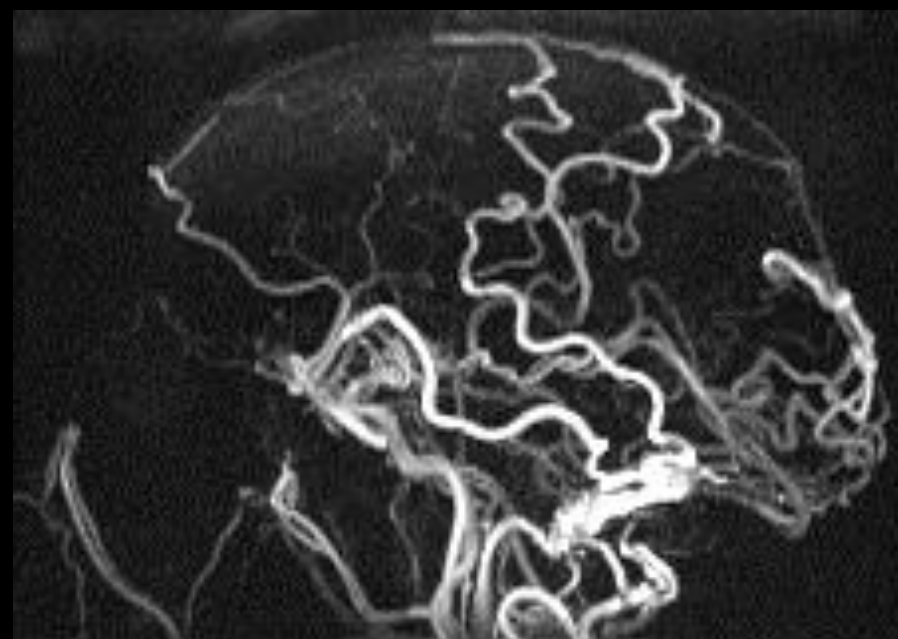
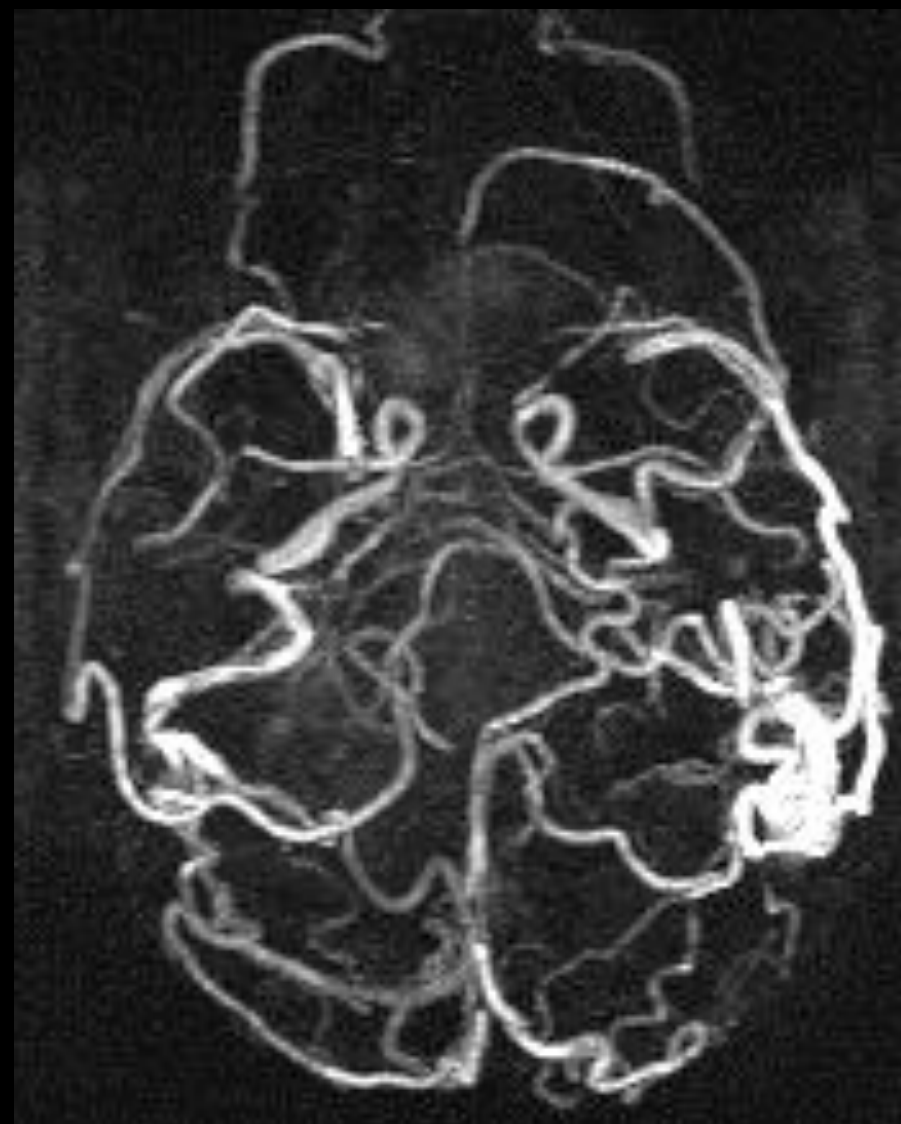16/1/07 P.S: Epilettico in progressa trombosi venosa

Seni durali, ematoma sottodurale cronico in terapia con
Coumadin. Trauma cranico accidentale. Disartria.

Clonie facciali. TC (negativa), RM, AGF

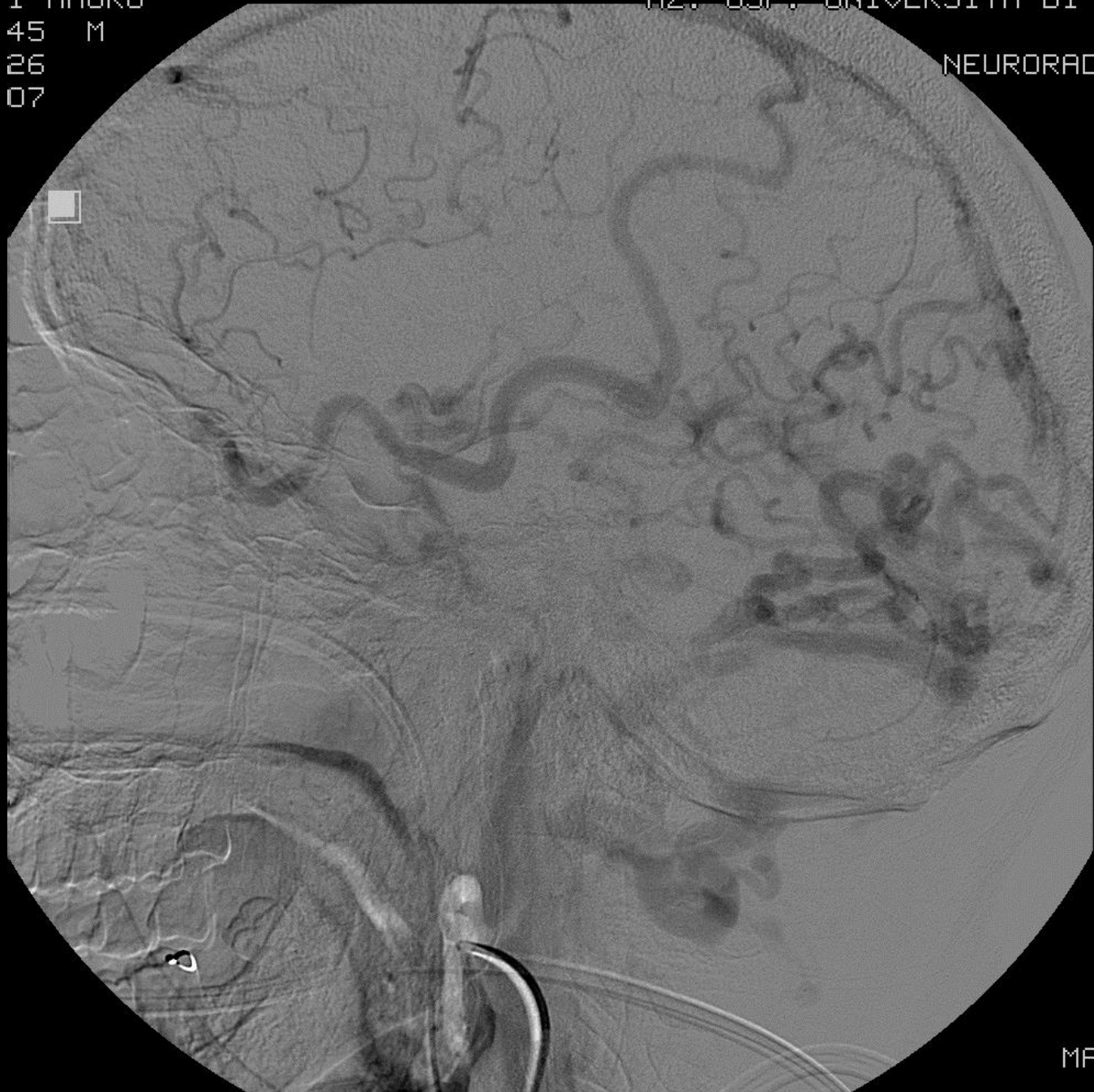






I MAURO
45 M
26
07

AZ. OSP. UNIVERSITA DI
NEURORAD



MA

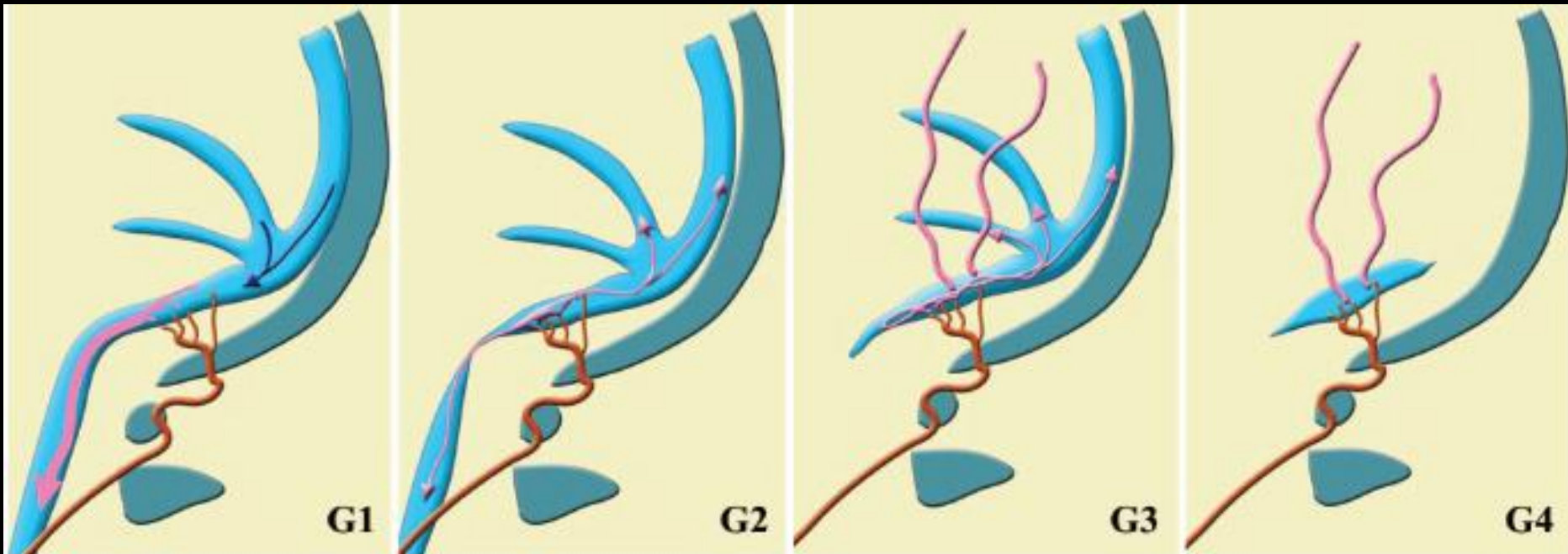
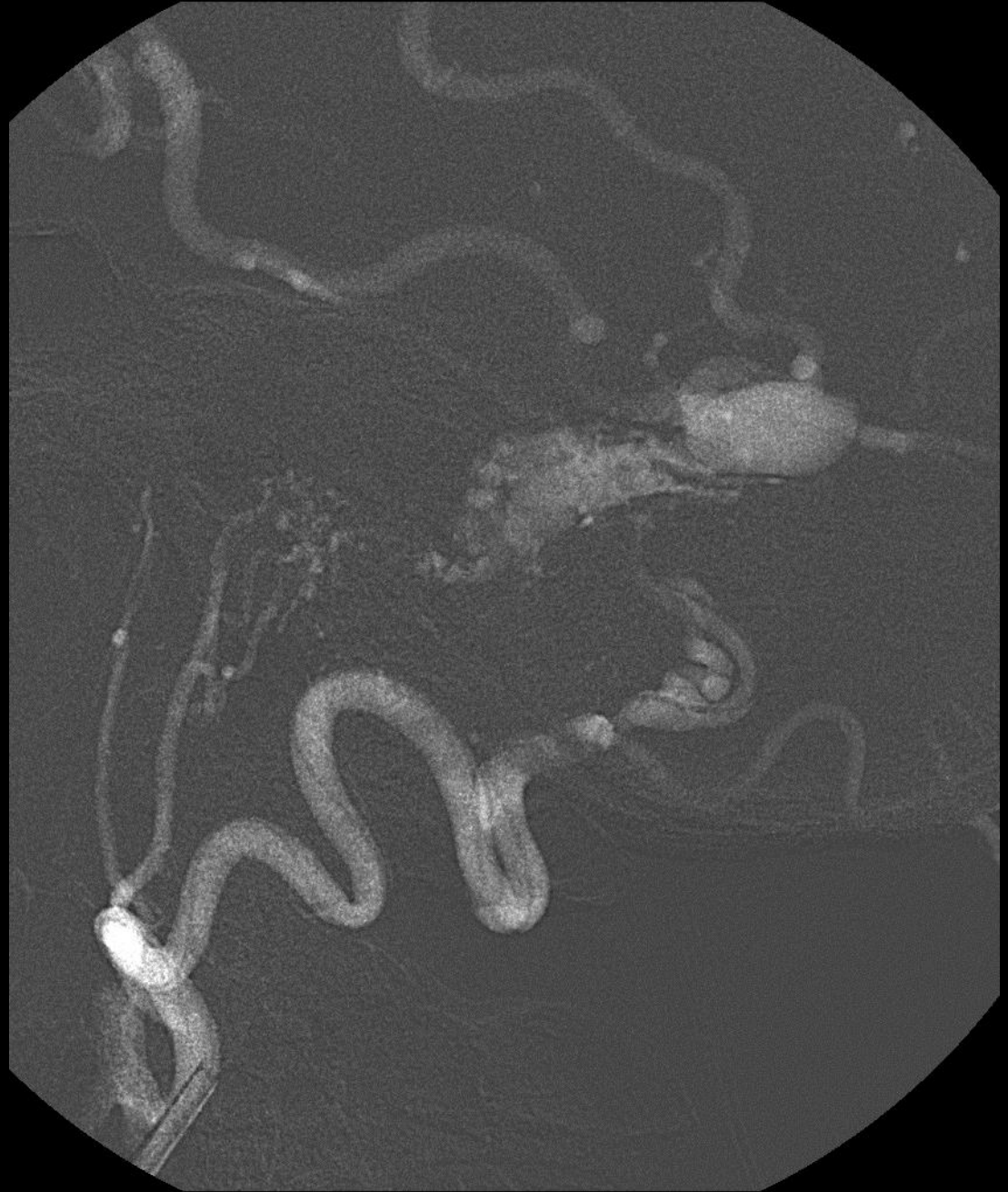
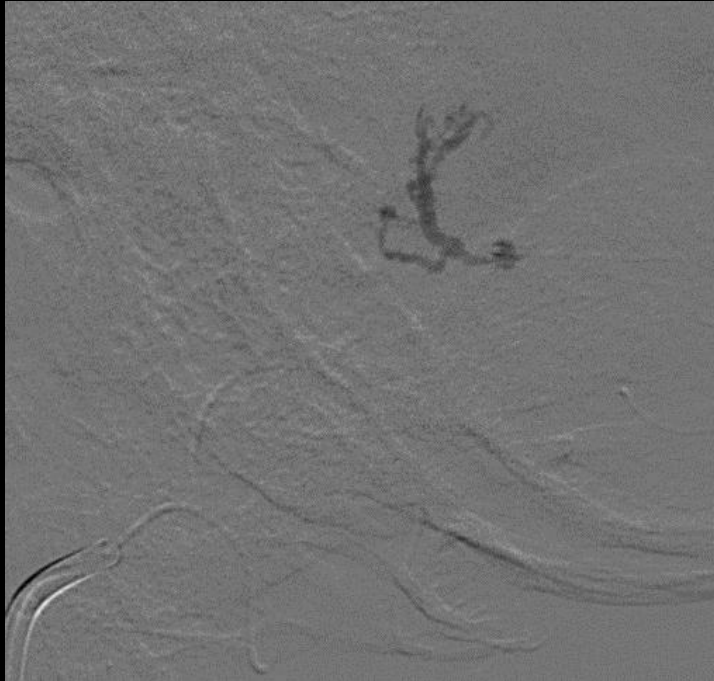


Figure 8. Drawings illustrate a classification scheme for transverse-sigmoid sinus dural AVFs that is based on venous drainage patterns: Grade 1, antegrade sinus drainage without venous restriction or cortical venous reflux; Grade 2, antegrade and retrograde sinus drainage with or without cortical venous reflux; Grade 3, retrograde sinus drainage with cortical venous reflux; and Grade 4, cortical venous reflux only. (Reprinted, with permission, from reference 11.)

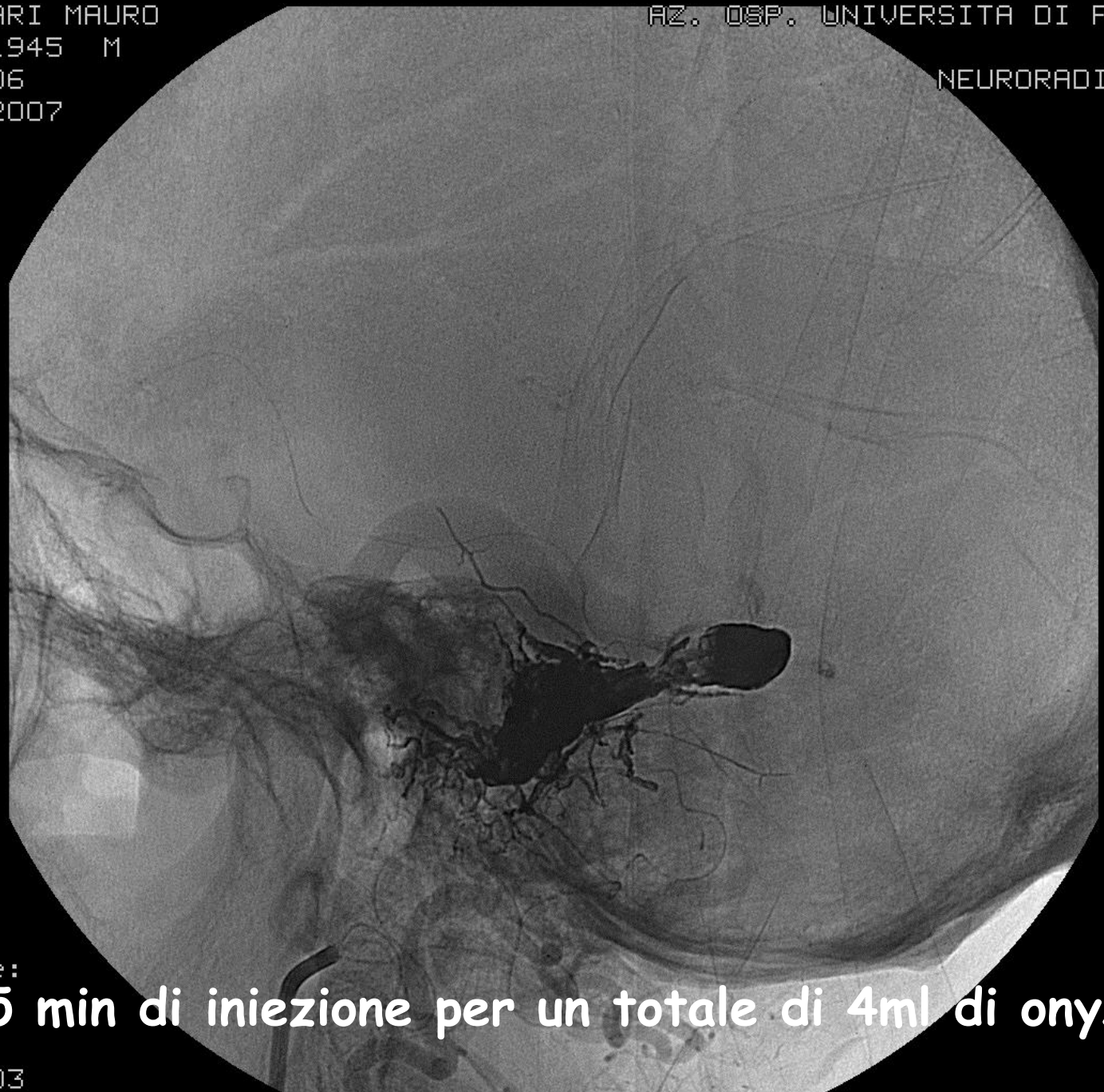Lalwani AK, Dowd CF, Halbach VV. Grading venous restrictive disease in patients with dural arteriovenous fistulas of the transverse/sigmoid sinus. *J Neurosurg* 1993; 79:11-15.



CALZOLARI MAURO
21-02-1945 M
07470806
04-04-2007

AZ. OSP. UNIVERSITA DI FERRARA

NEURORADIOLOGIA



ROT
93

ANG
0

RUN
21
25
IMAGE
13

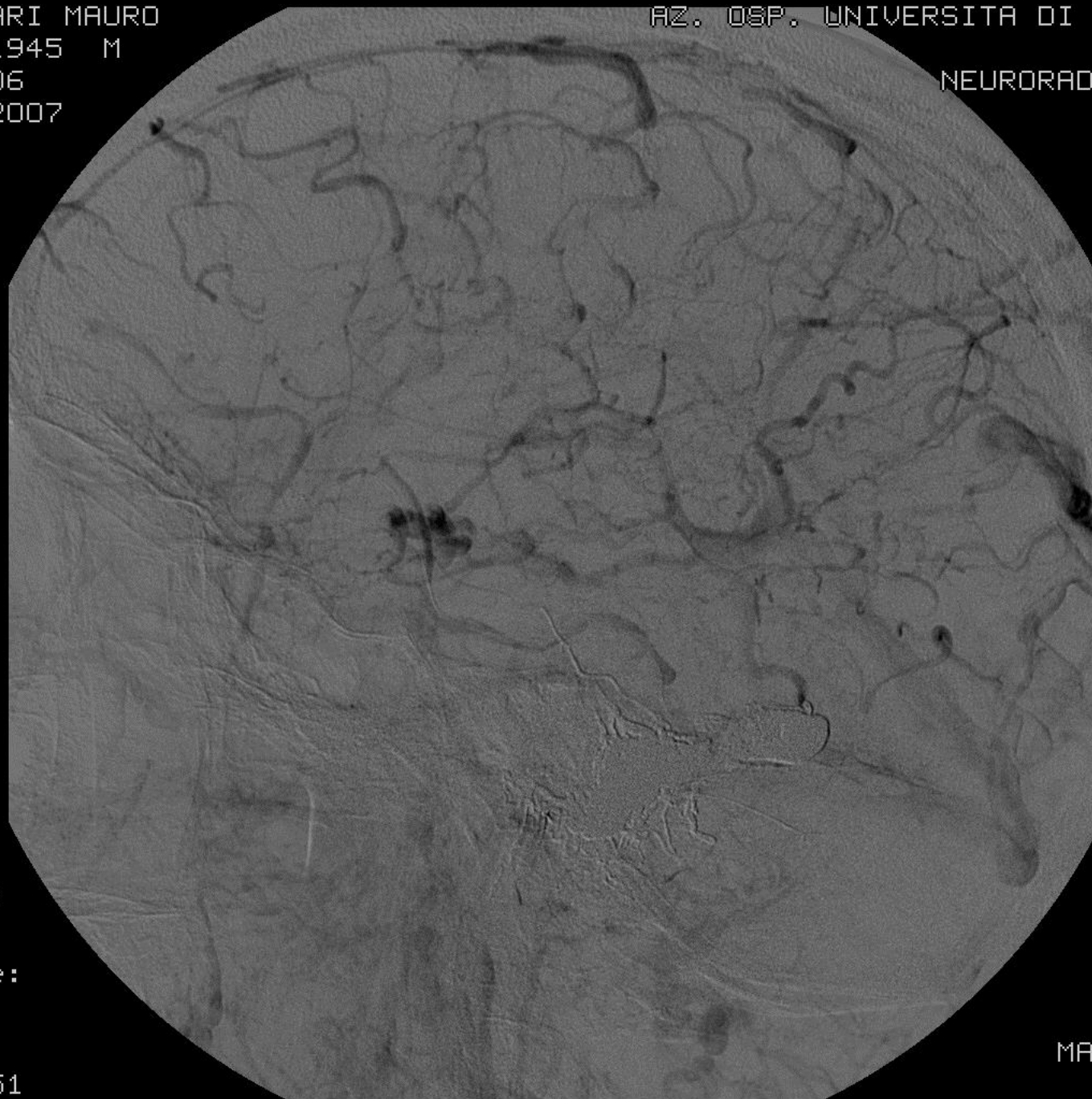T-image:
13:04
1 h 45 min di iniezione per un totale di 4ml di onyx

T-run:
15:00:03

CALZOLARI MAURO
21-02-1945 M
07470806
04-04-2007

AZ. OSP. UNIVERSITA DI FERRARA

NEURORADIOLOGIA



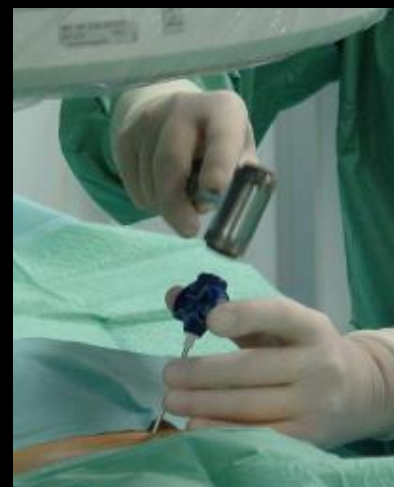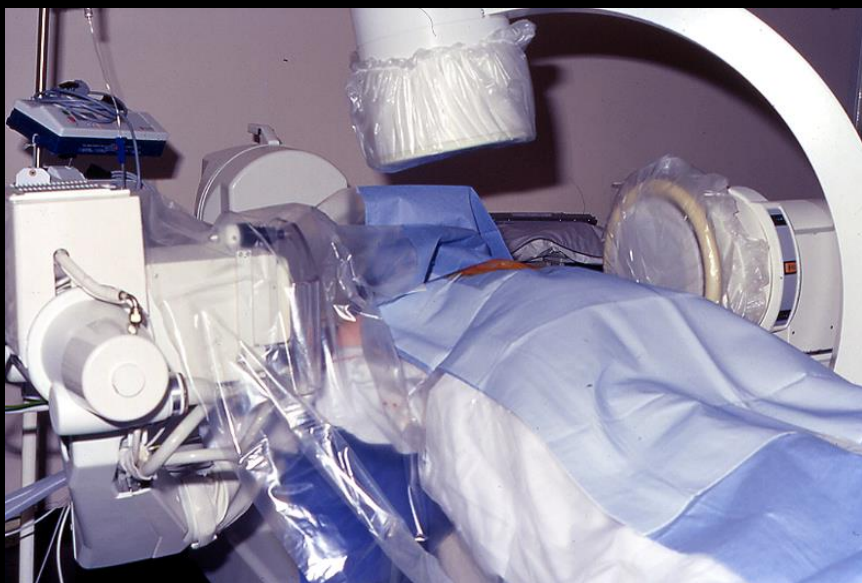ROT
93

ANG
0

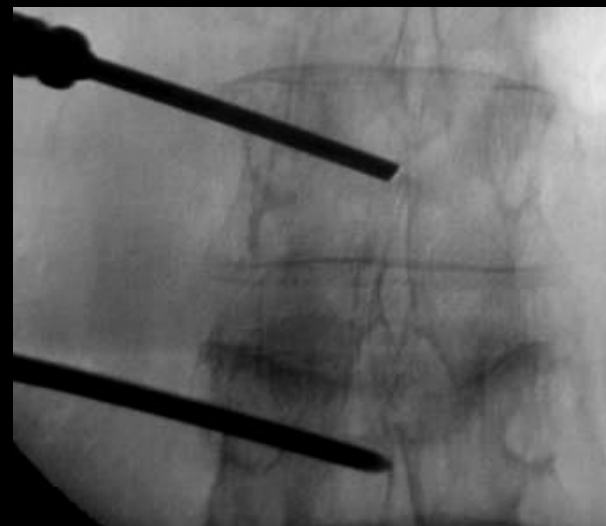T-mask:
0.32
T-image:
12.76
T-run:
15:06:51

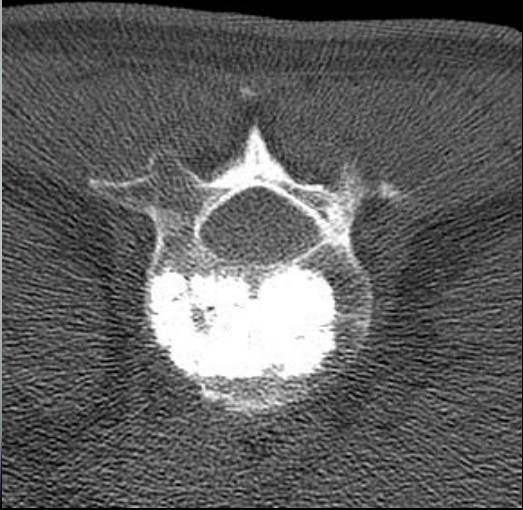
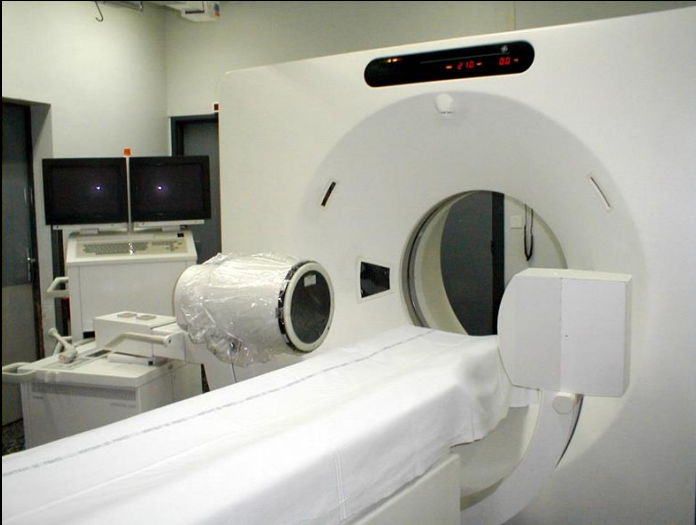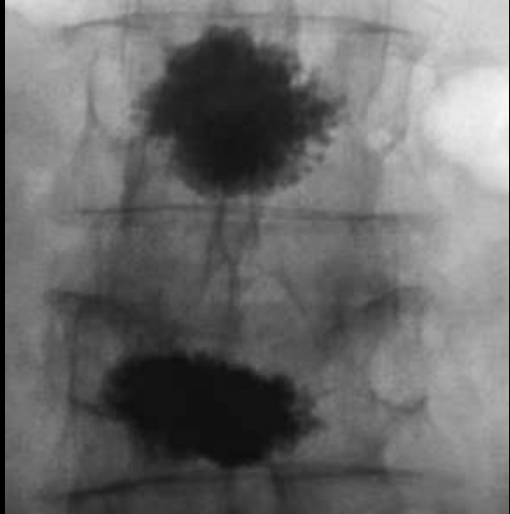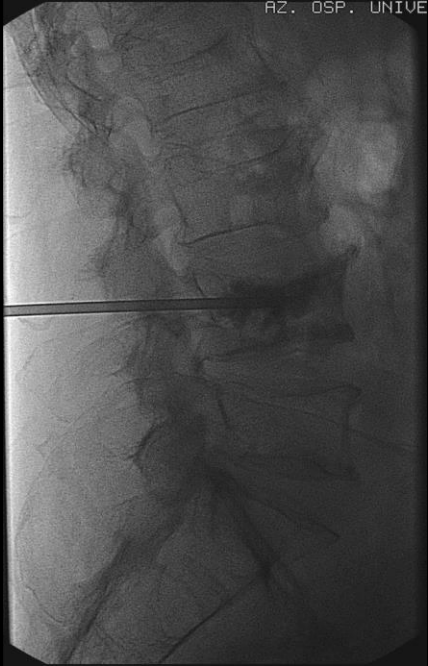
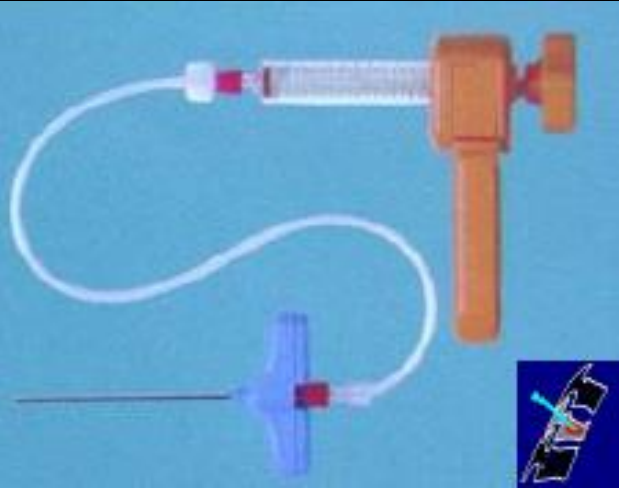
RUN
22
28
MASK IMAGE
2 26

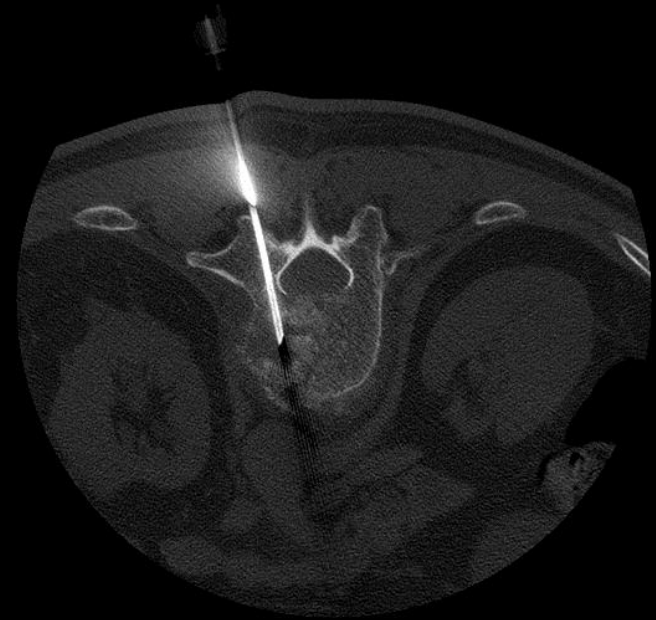
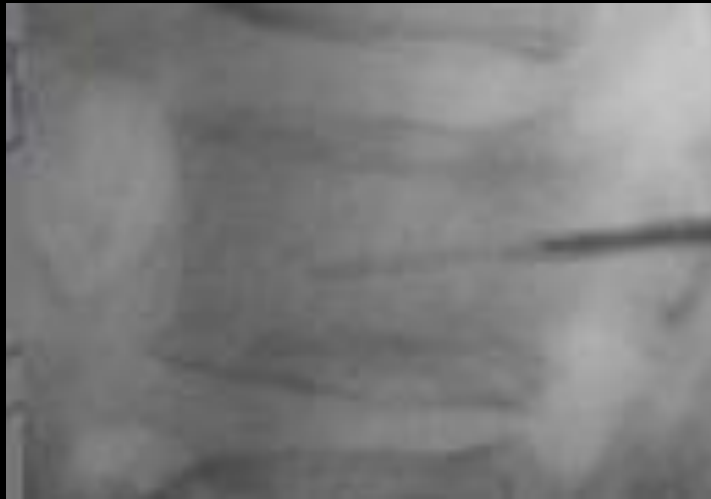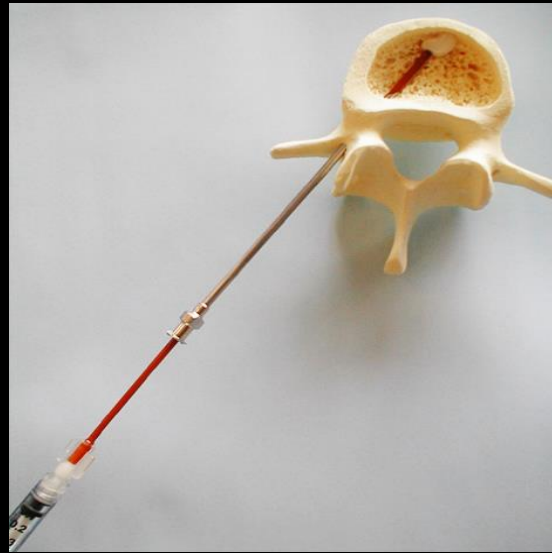
VERTEBROPLASTICA BIOPSIE



**INTRODUZIONE DELL'AGO
CON CONTROLLO FLUOROSCOPICO**





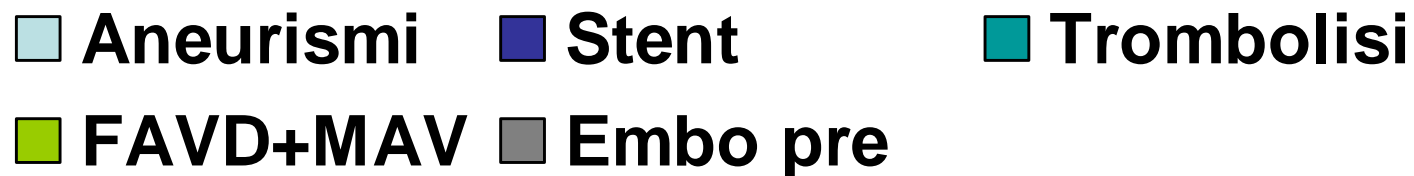
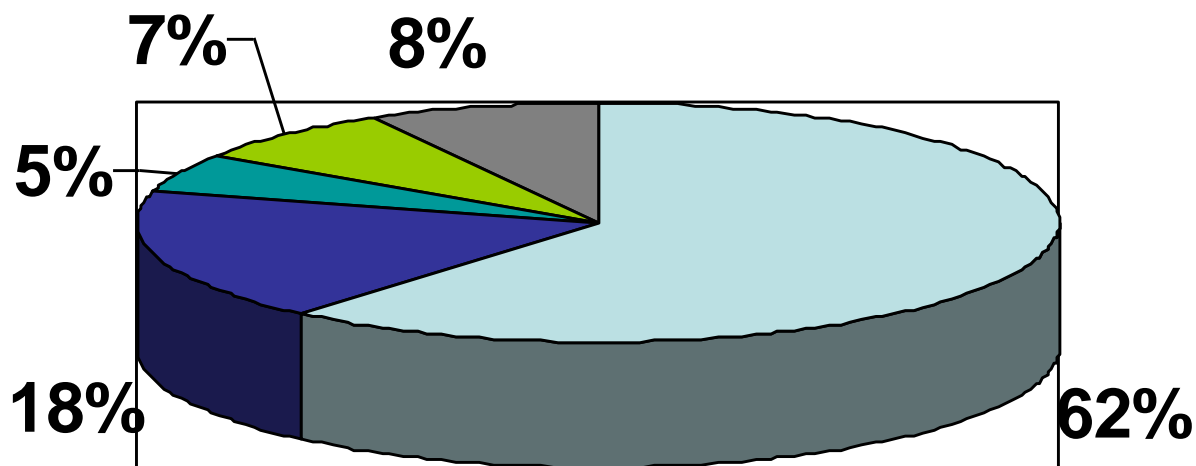


NEURORADIOLOGIA INTERVENTISTICA

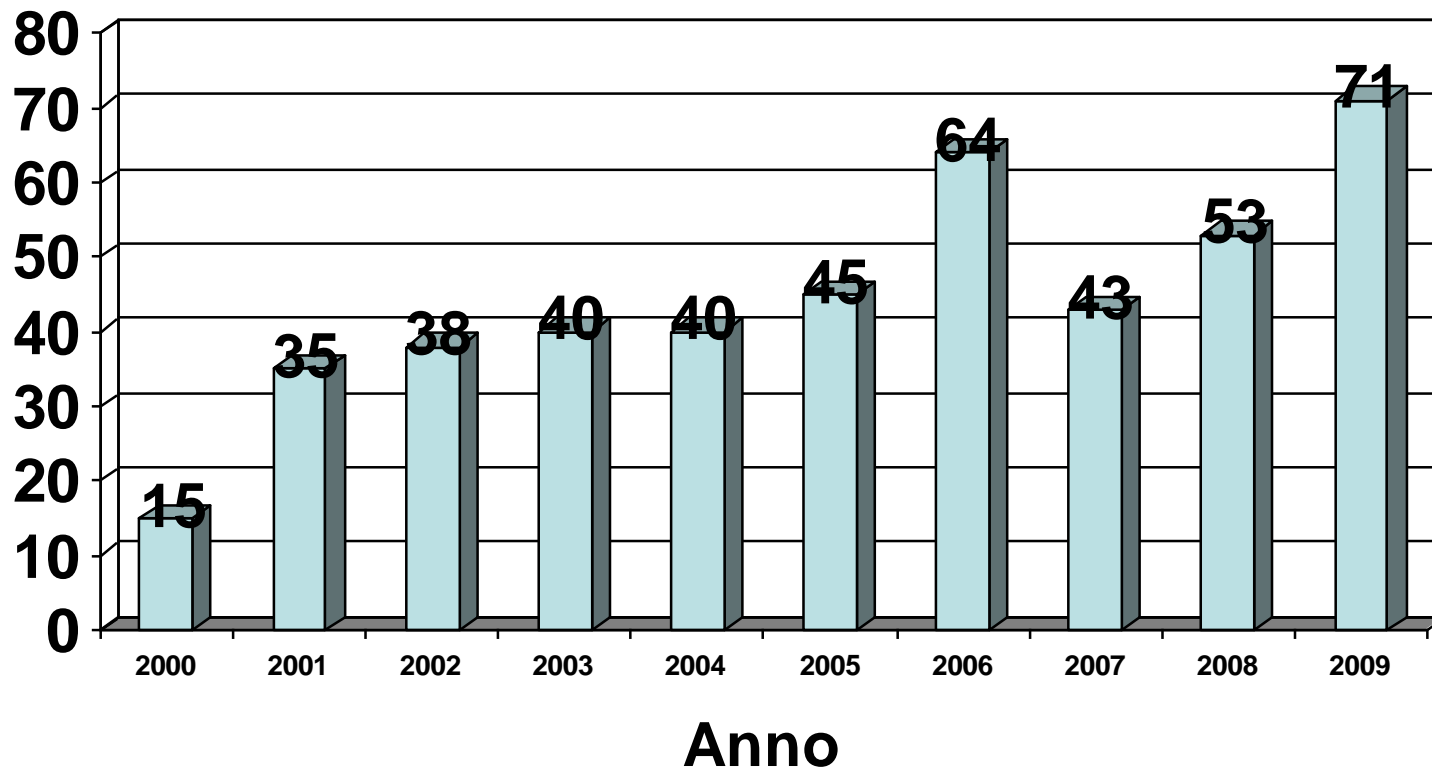
2000-2009

- **200 Aneurismi cerebrali**
- **44 Stent carotidei**
- **20 Trombolisi (7 nel 2007)**
- **11 Fistole**
- **8 MAV**
- **20 Embolizzazioni preoperatorie**
- **140 Vertebroplastiche**

Tipologia di interventi



N° Interventi/anno



Tot. Interventi 440 (media 44/anno)



SERVIZIO SANITARIO REGIONALE
EMILIA-ROMAGNA
Azienda Ospedaliero - Universitaria di Ferrara



università di ferrara
DA SEICENTO ANNI GUARDIAMO AVANTI



Incontro con Sindacati Aziendali 04/11/2009

verso CONA